

# FNA of Breast

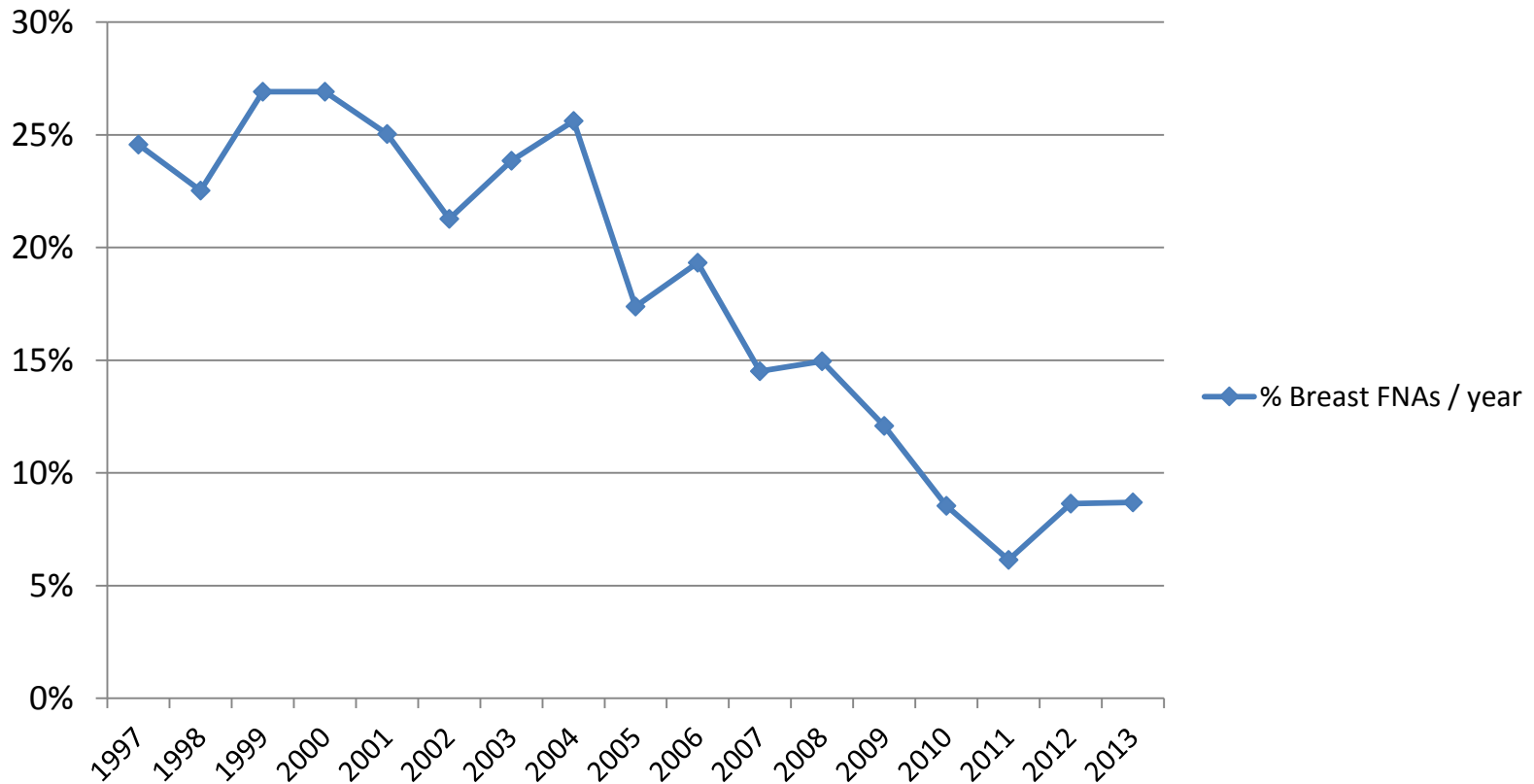
Nina S Shabb

AUBMC



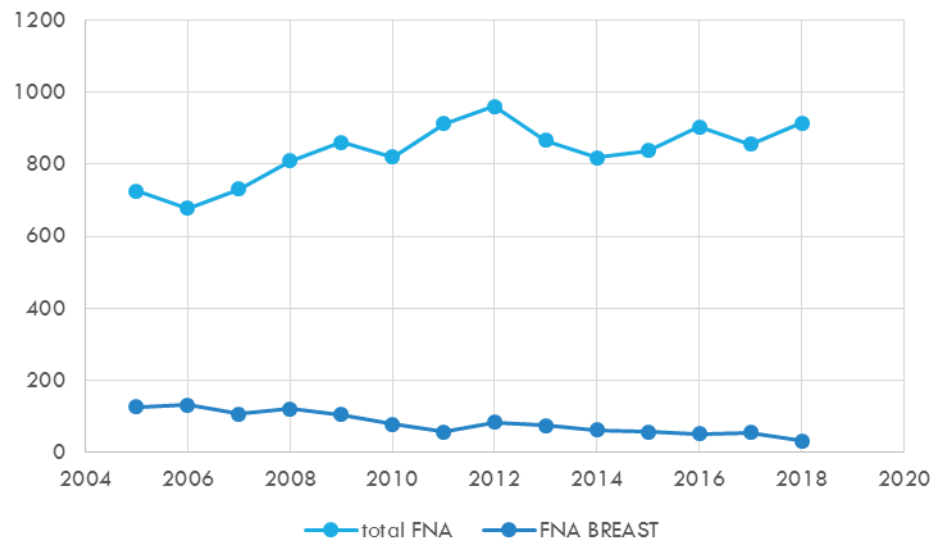
# % of Breast FNAs 1997-2013: AUBMC

## % Breast FNAs / year



# AUBMC breast FNA statistics 2005-2018.

year	total FNA	FNA BREAST
2005	725	126
2006	678	131
2007	730	106
2008	809	121
2009	860	104
2010	819	77
2011	912	56
2012	960	83
2013	866	75
2014	818	61
2015	838	56
2016	904	52
2017	855	54
2018	915	31



# Objective

- All you need to know on FNA of breast.

# ↓ Role of breast FNA

## Why?

- DICS vs. Invasive ca
  - Not clinically relevant in majority of cases
- CNB needed for ancillary studies
  - Can be done on excision specimen
- Clinical trials require histologic diagnosis
  - May not be relevant
- Confirmation of malignancy by CNB or FS
  - Not if a well trained and experienced cytopathologist is available and if TT is concordant
- Cytopathology expertise not always available
  - True

# Established role

- Recurrent mass in breast in patient with history of breast ca.
- Some centers particularly in economically challenged areas rely on FNA.
- Axillary lymph node mets

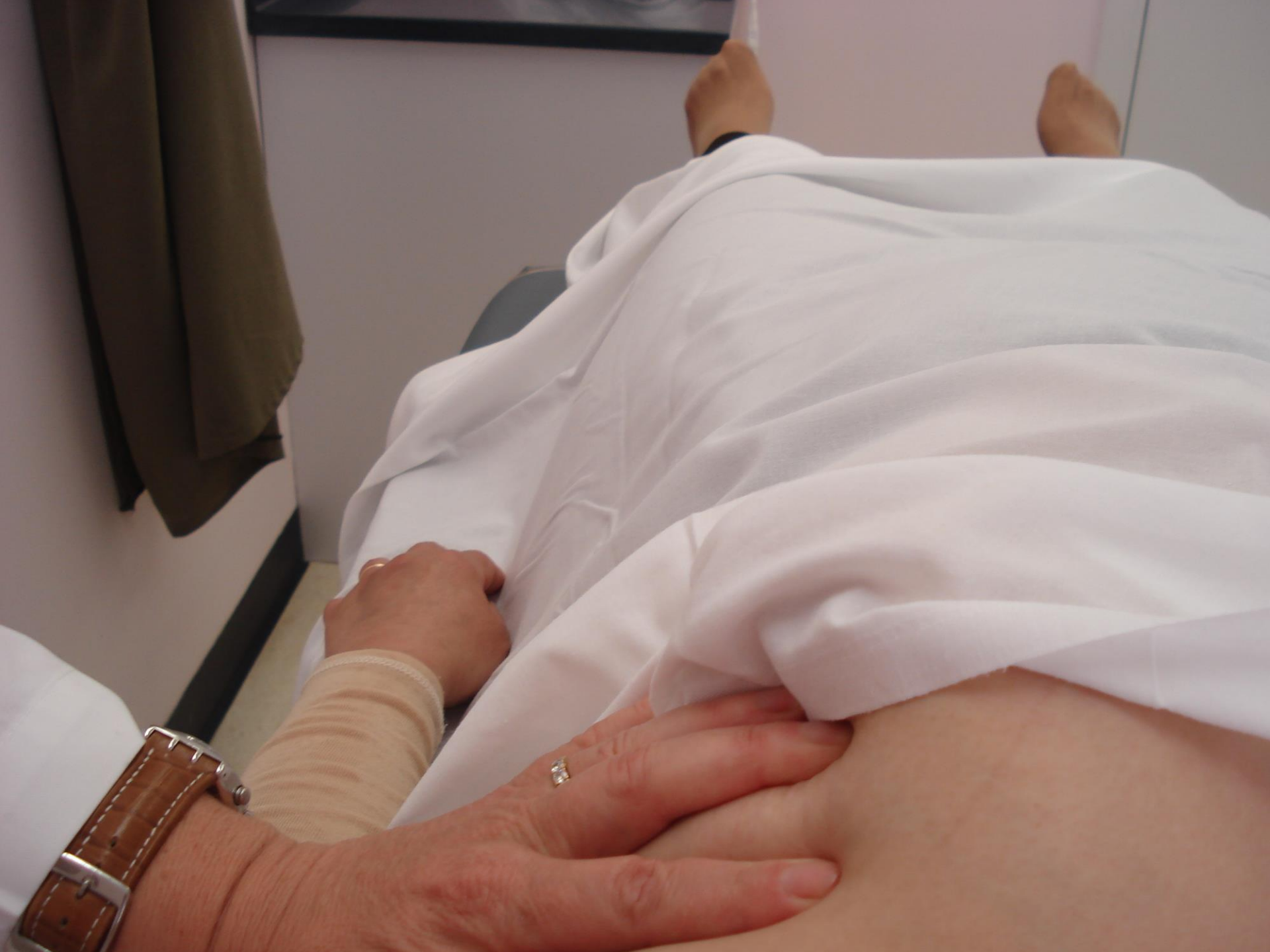# Performing breast FNA

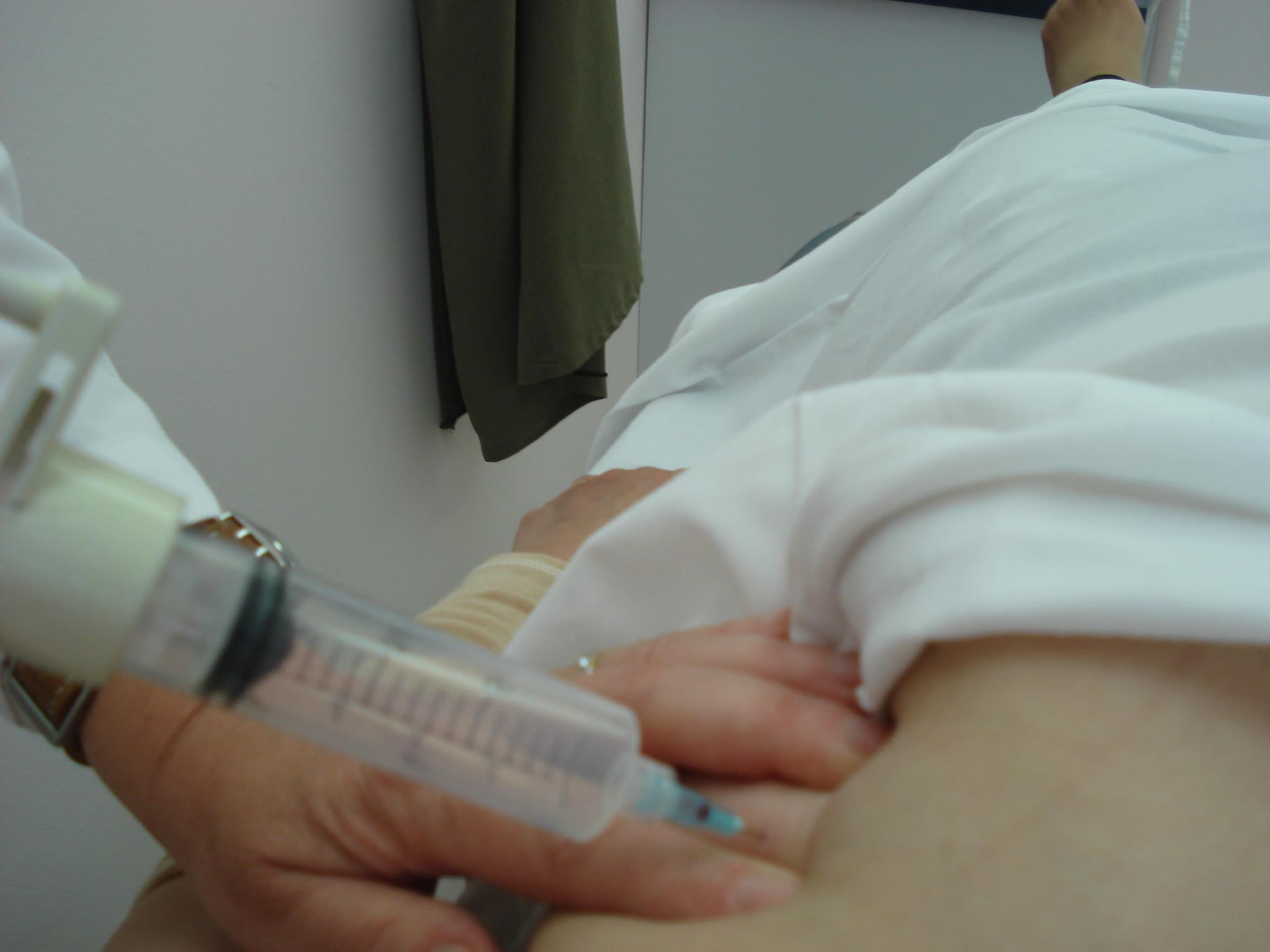# Who should perform the FNA?

- The person who is going to read it!



No real cost





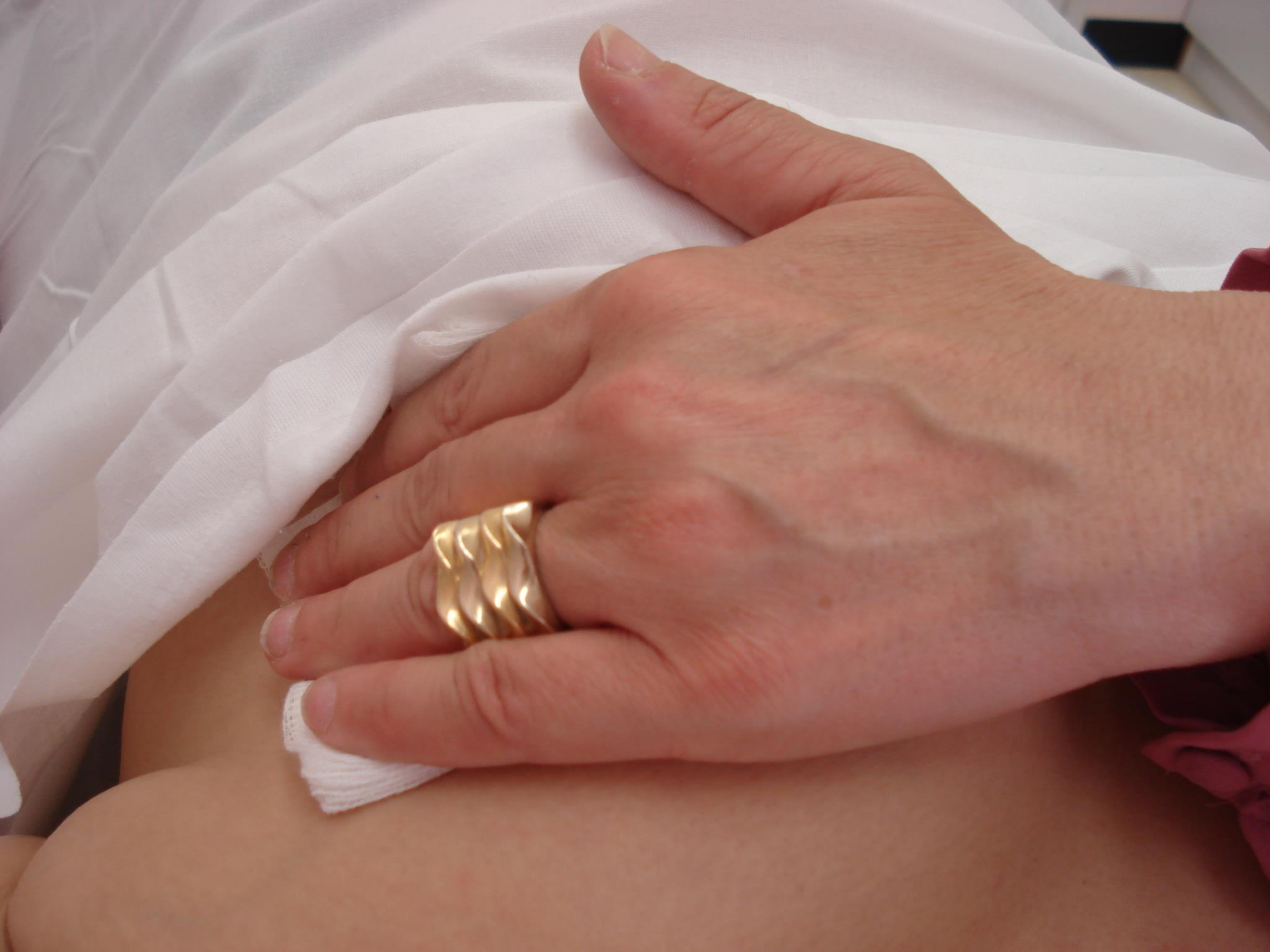Sumner  
Mason

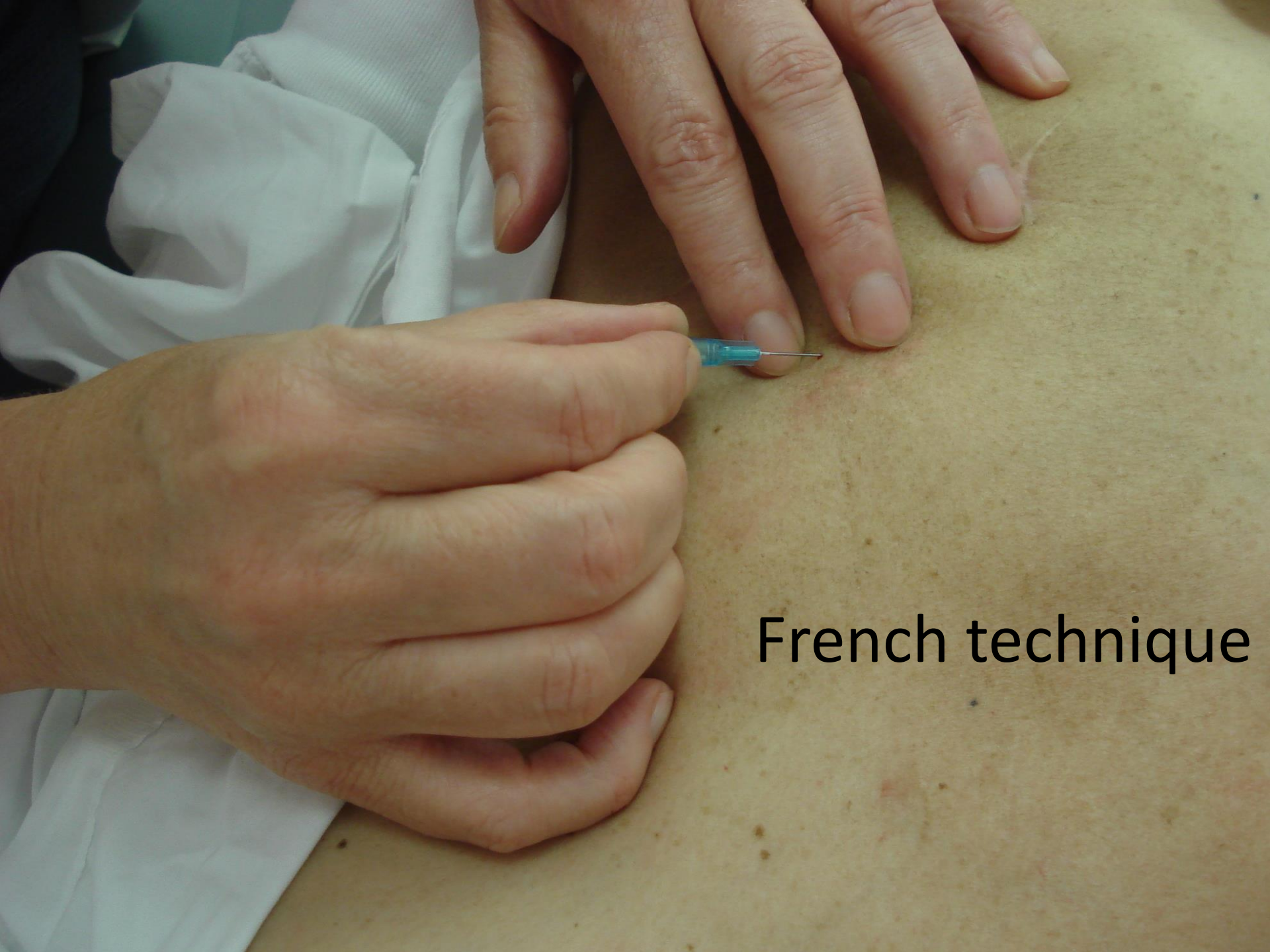
Sumner  
Mason

Sumner  
Mason









French technique

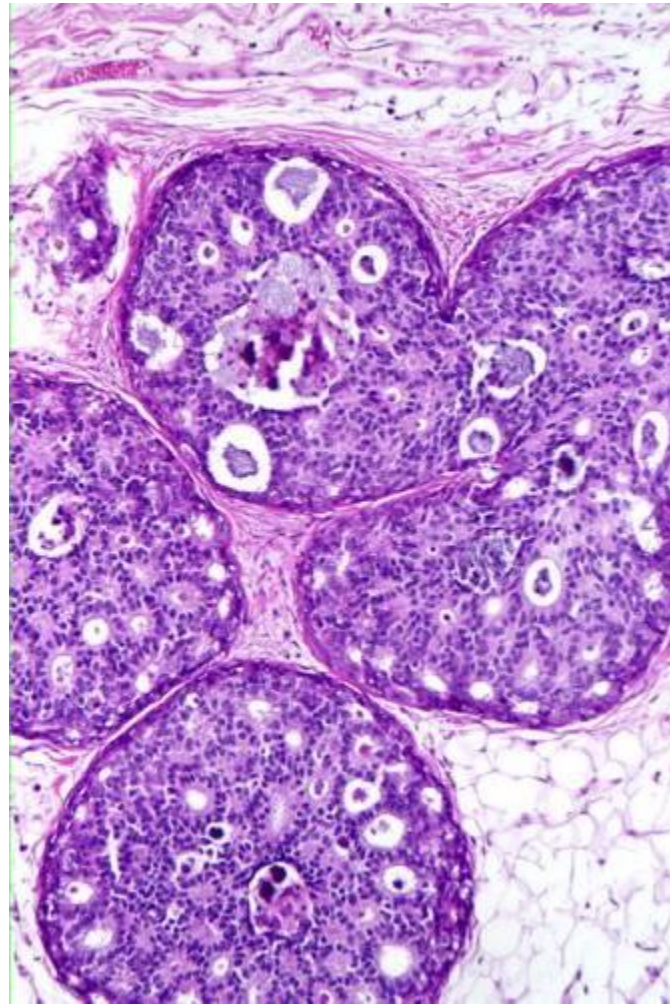
Carcinoma





**Benign breast disease**

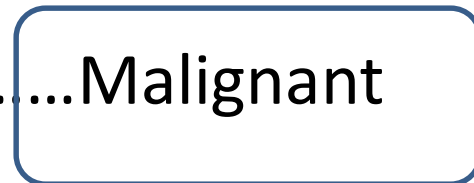# DCIS



Looking at smears	Diagnostic categories
I don't have enough material ?!	C1 (Unsatisfactory)
I'm sure its benign	C2 (Benign)
Looks benign but I am not 100%	C3 (Atypical favor benign)
Looks malignant but I am not 100%	C4 (Atypical favor malignant)
I'm sure its malignant	C5 (Malignant)

# 1. Easy to Diagnose Lesions

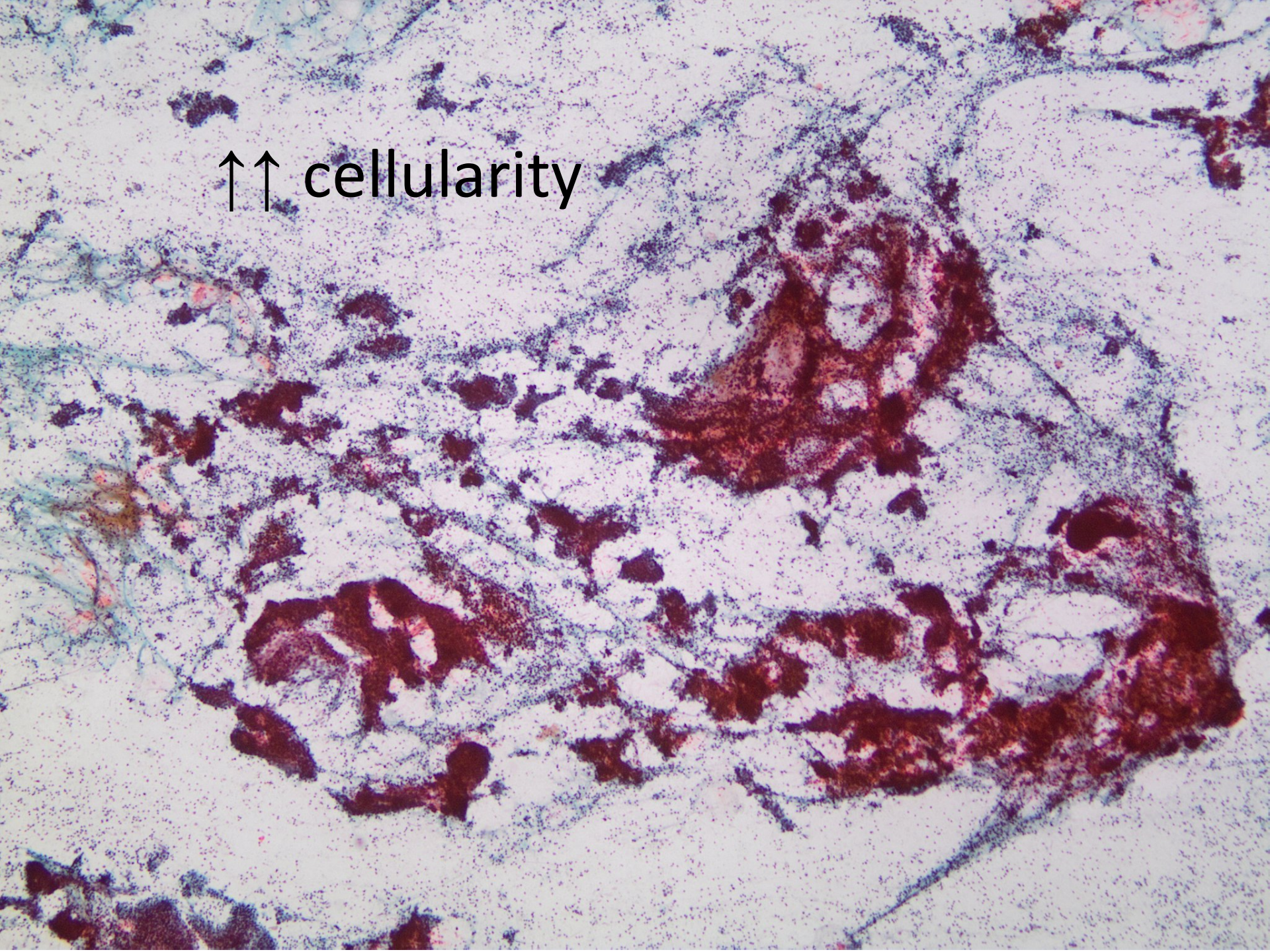
Benign.....Malignant



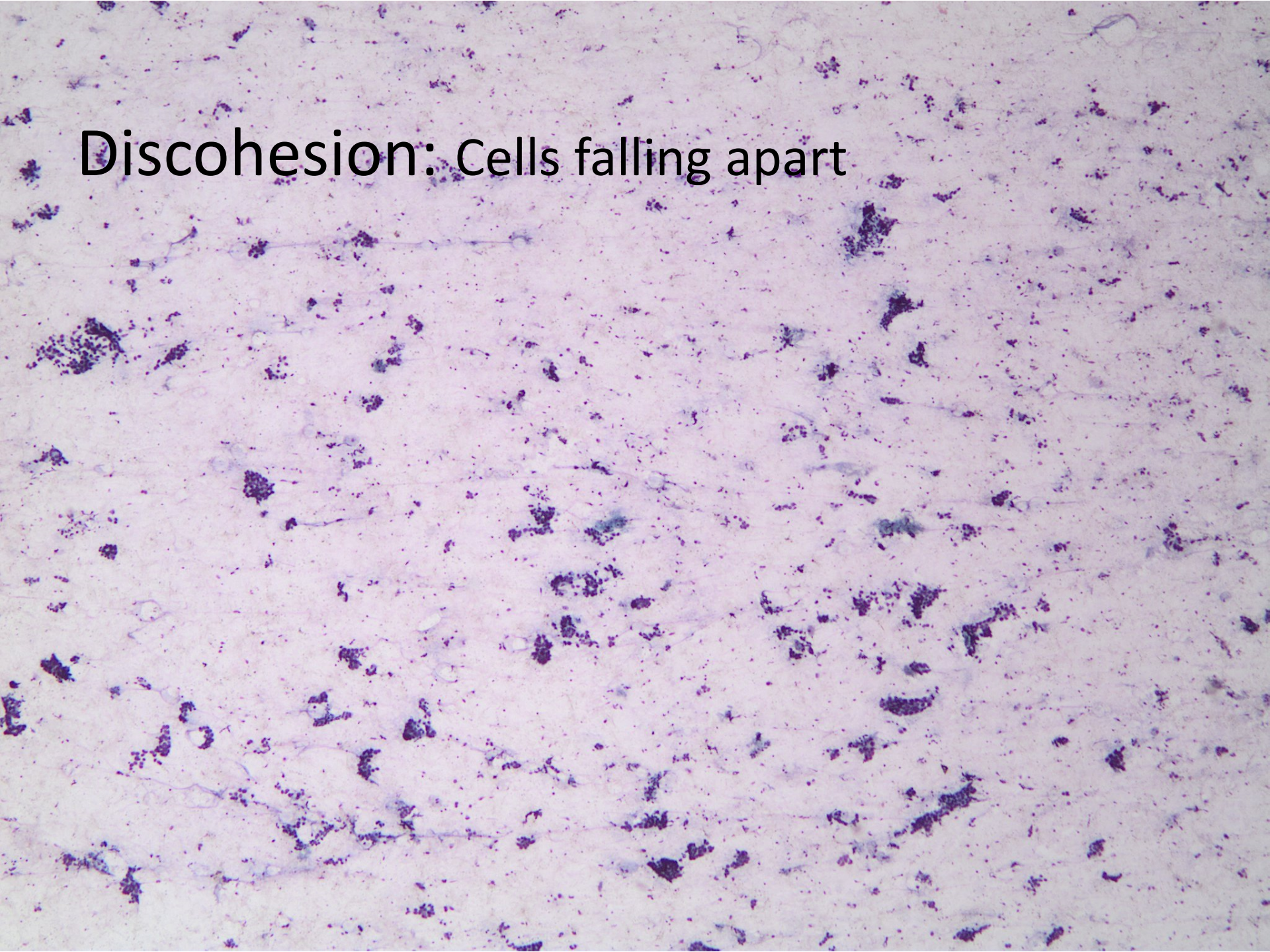
# Case

- 50 F, 4cm firm fixed mass, skin dimpling, nipple retraction.
- FNA Feel: Gritty
- Aspirated material: No fluid

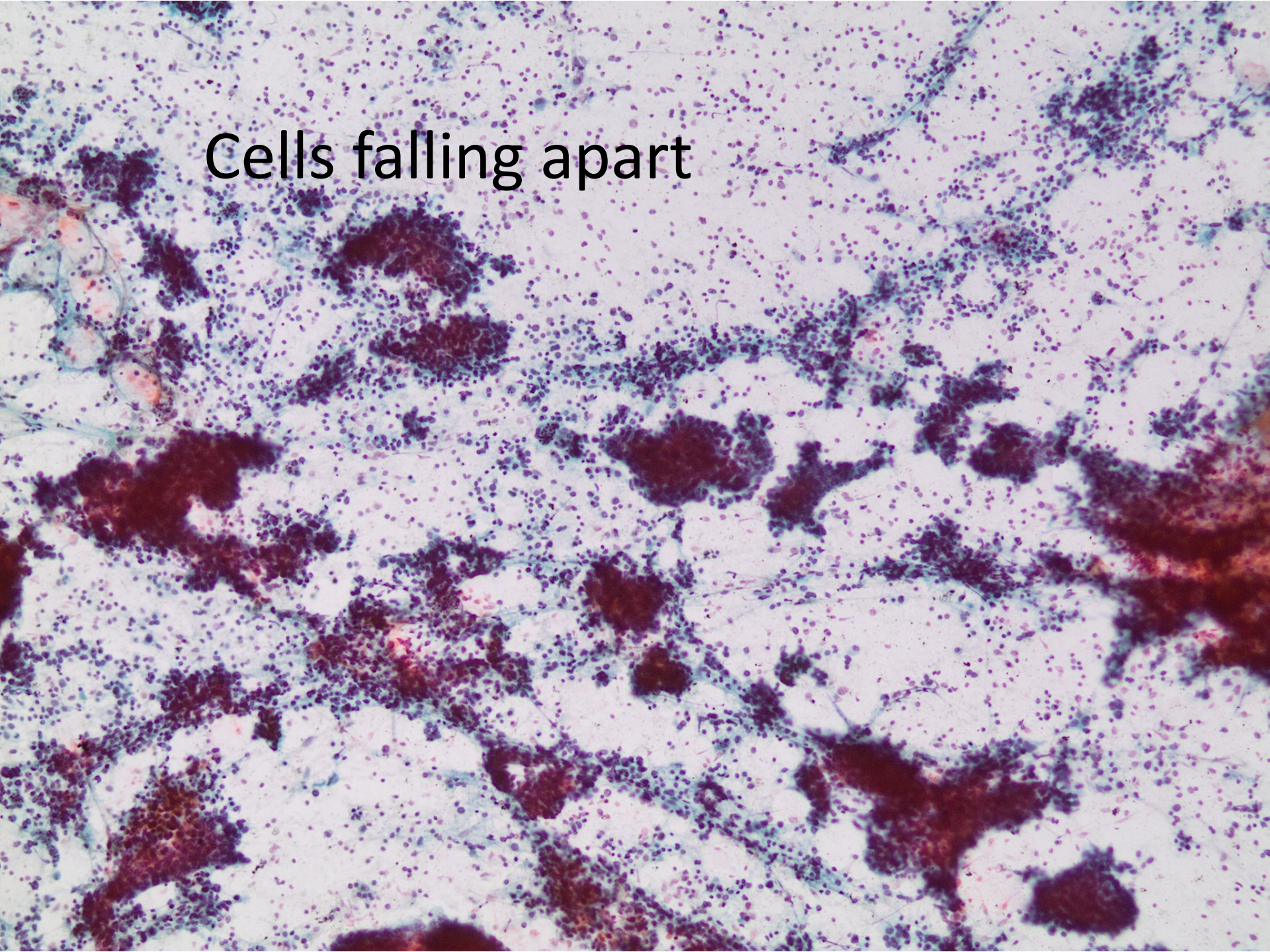
↑↑ cellularity



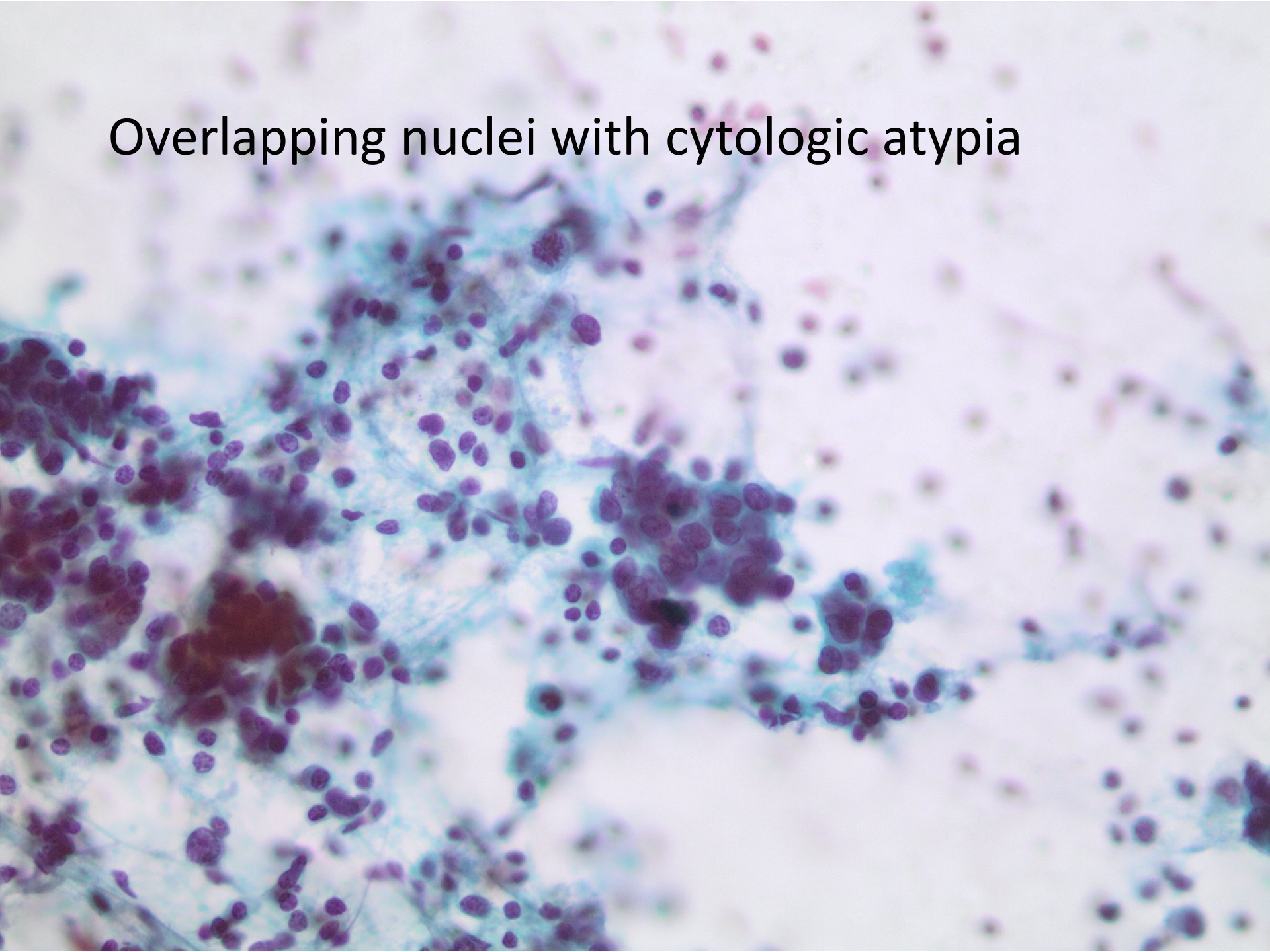
**Discohesion: Cells falling apart**



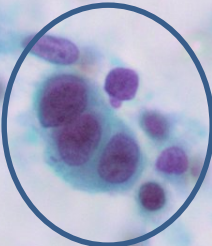
Cells falling apart

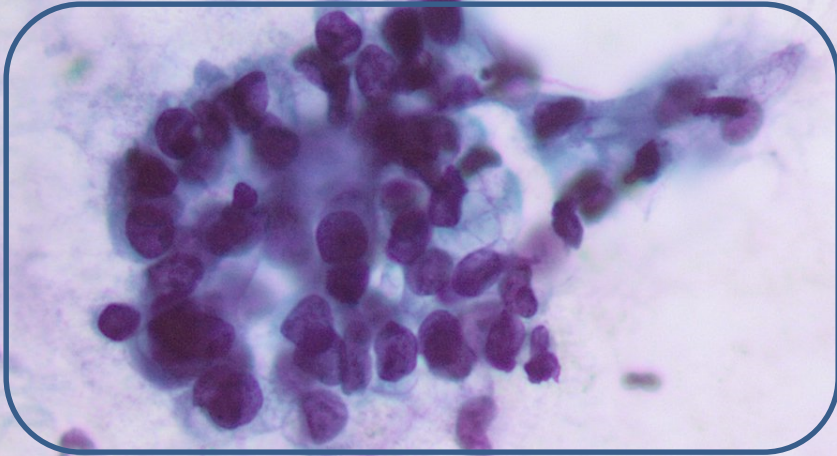


Overlapping nuclei with cytologic atypia

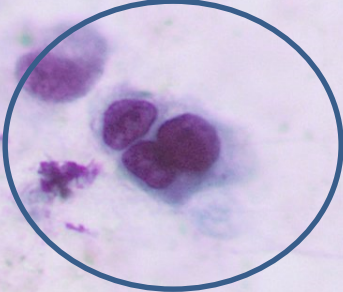


Small groups, intact cytoplasm

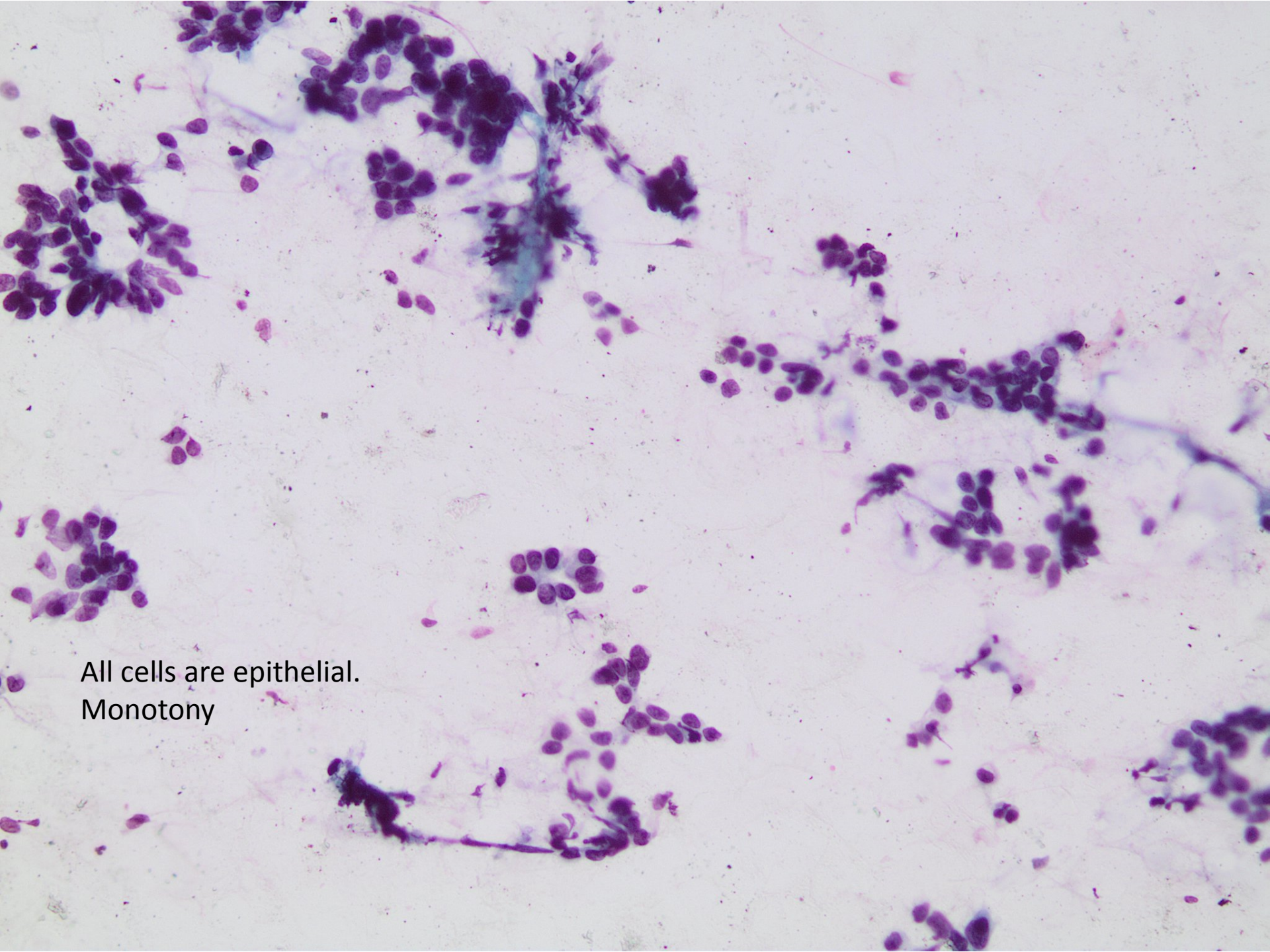




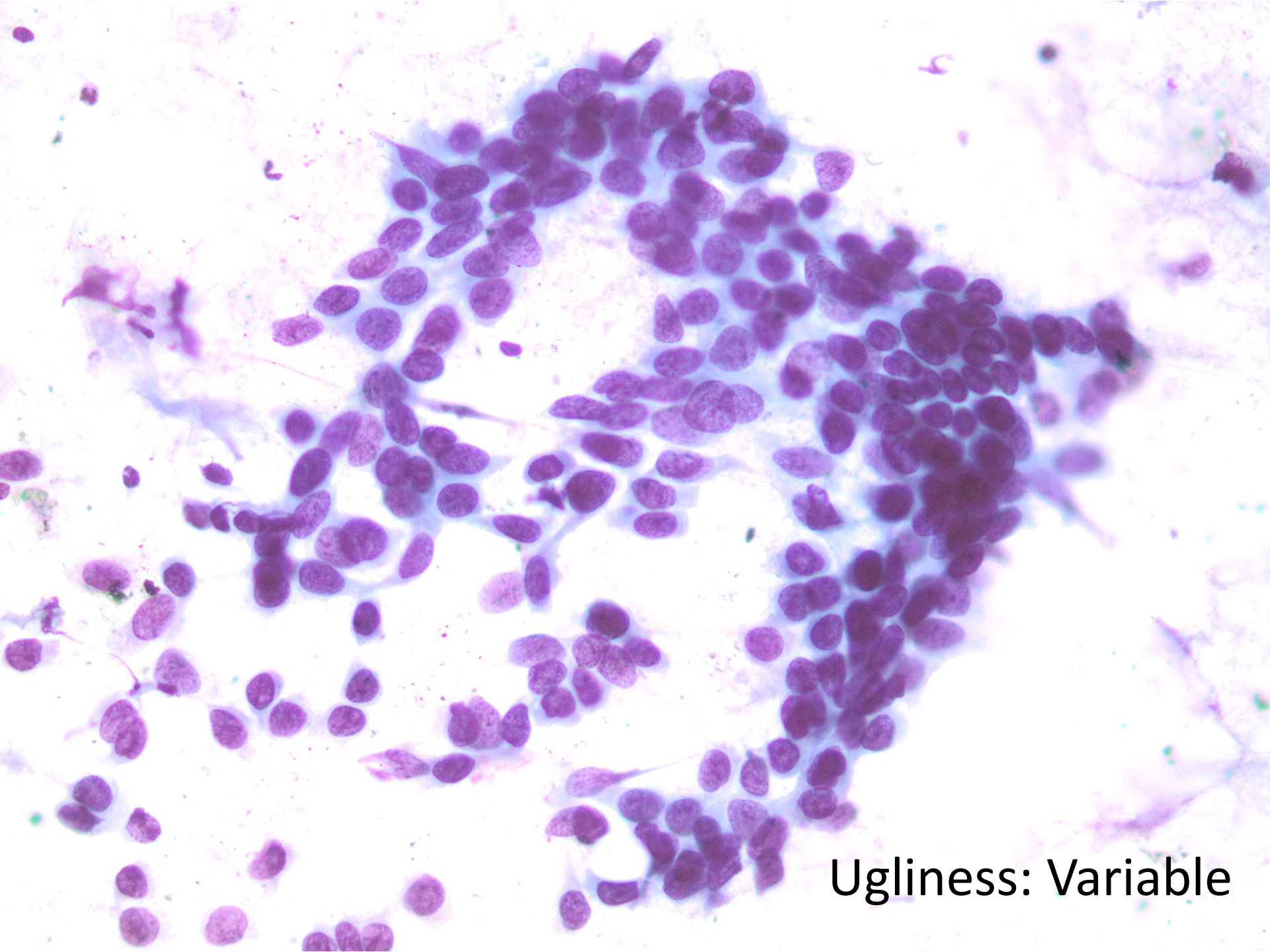
Loss of honeycombing



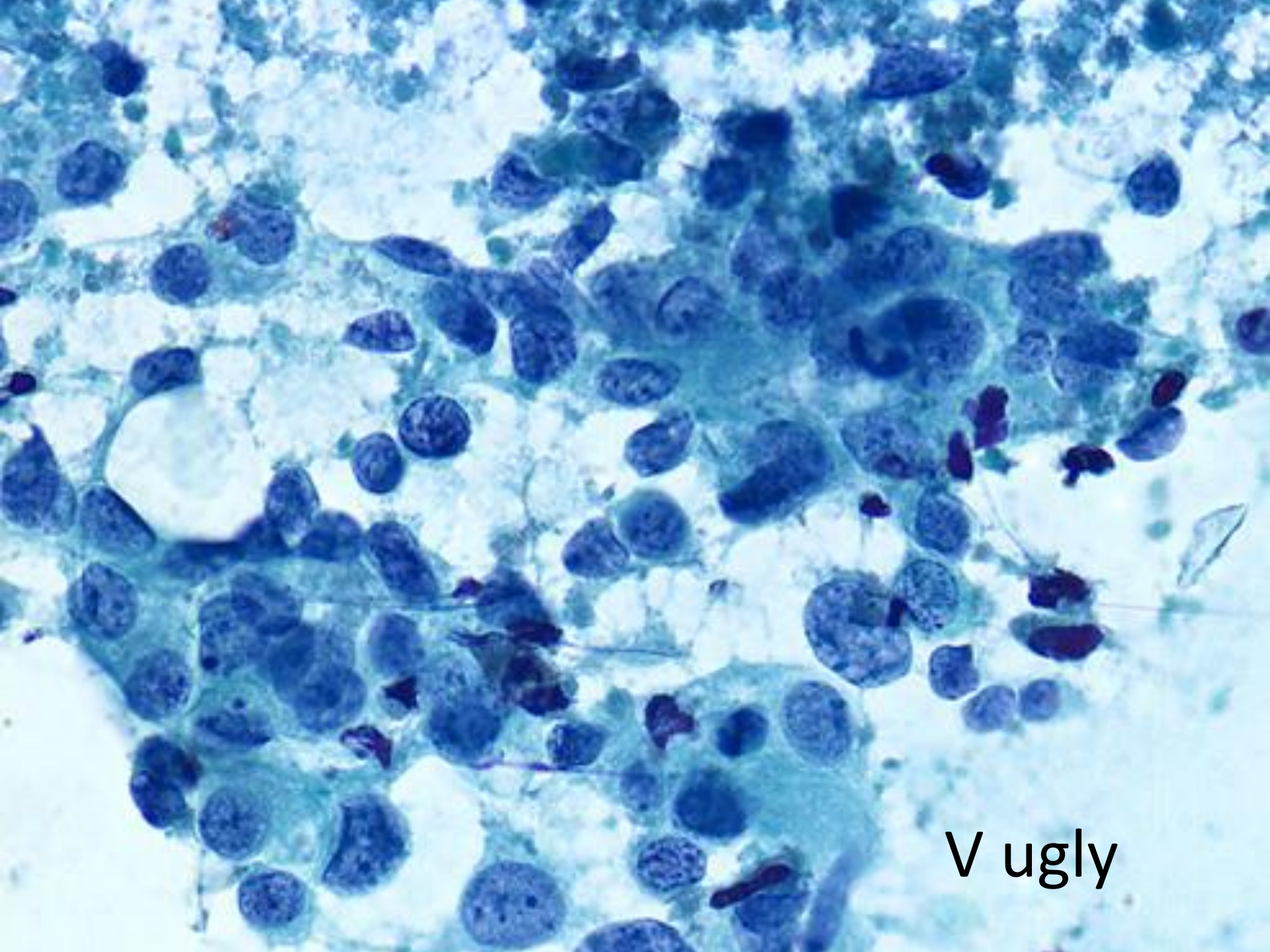
Single cells, intact cytoplasm



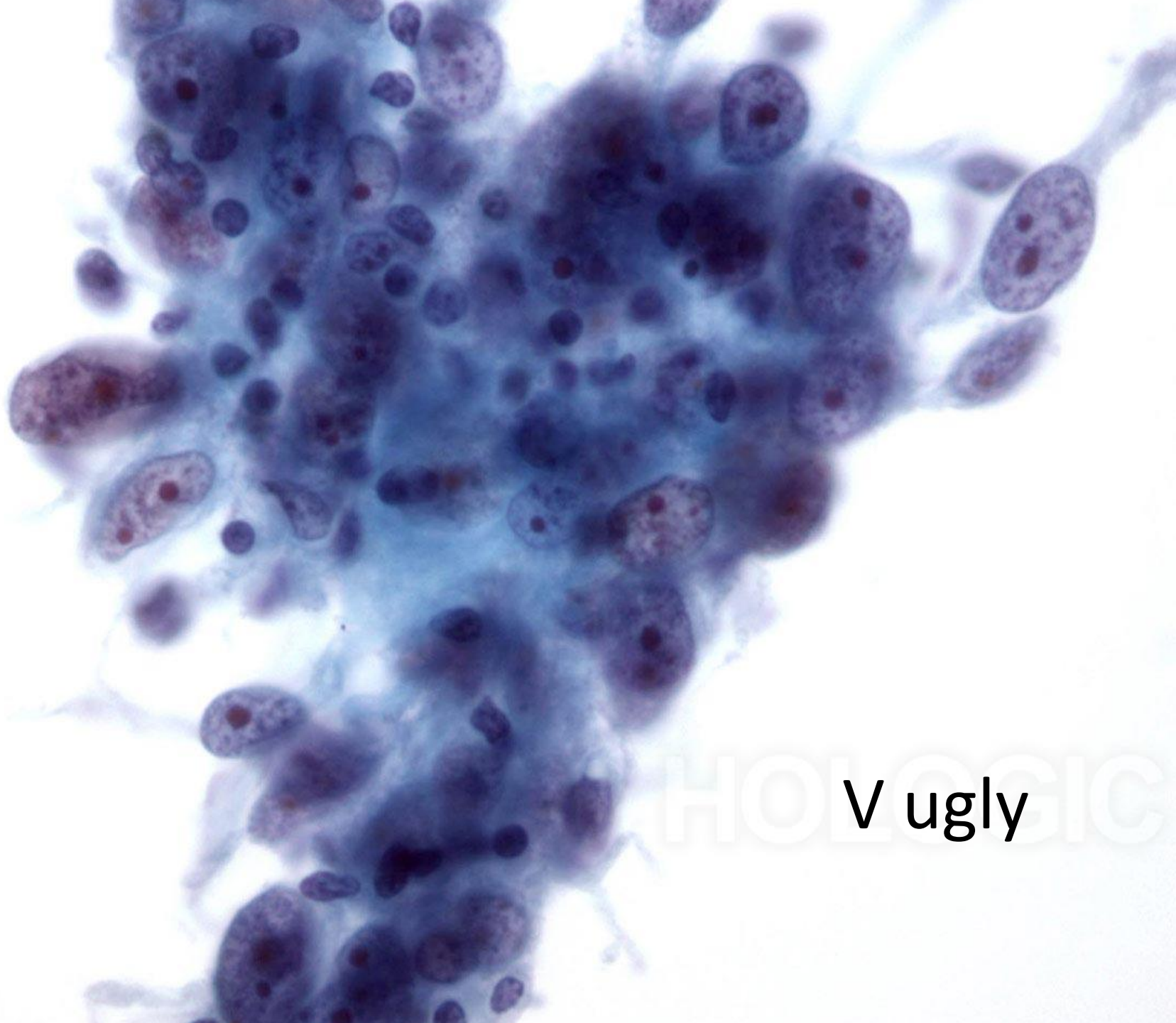All cells are epithelial.  
Monotony



Ugliness: Variable

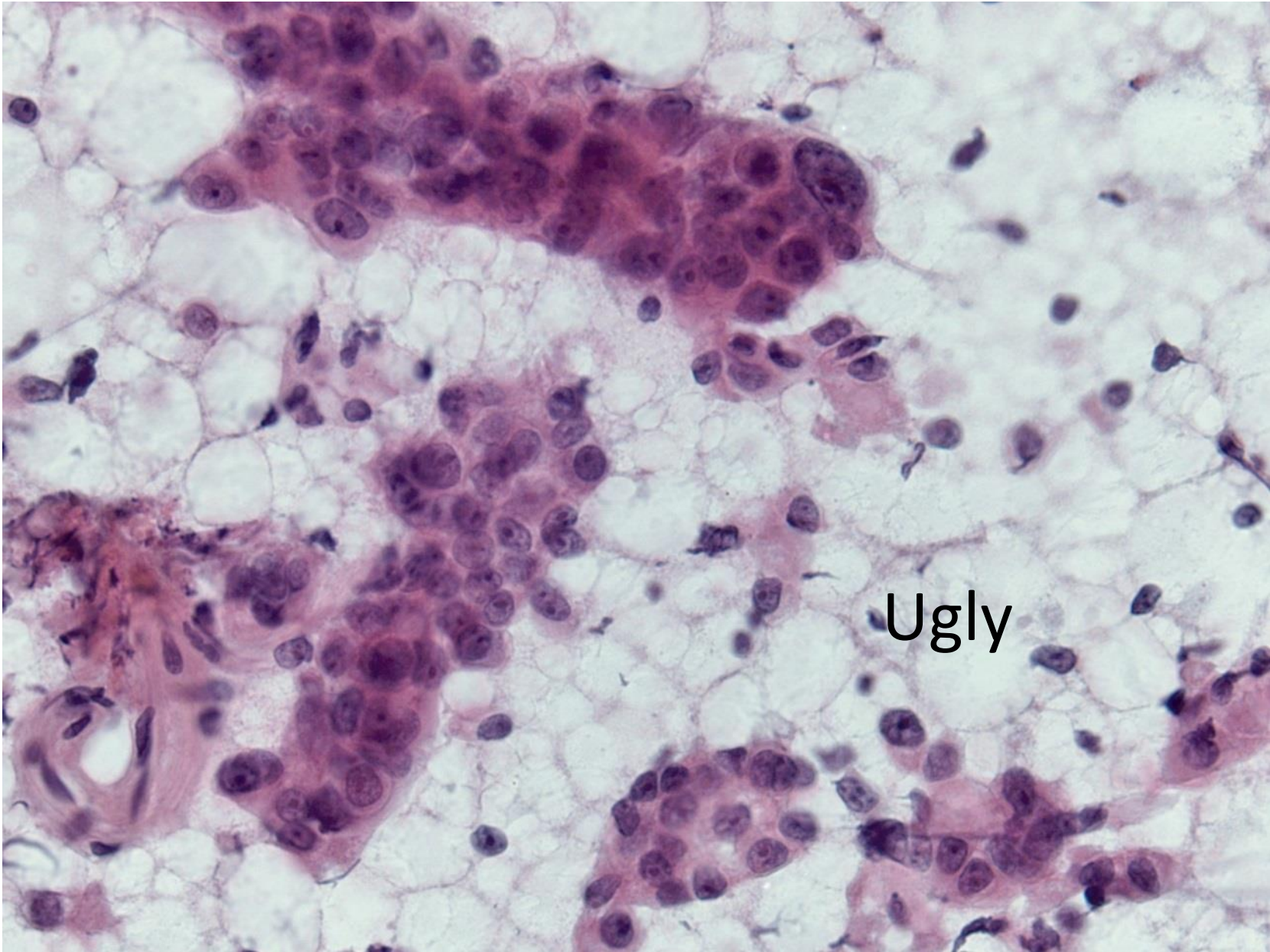


V ugly



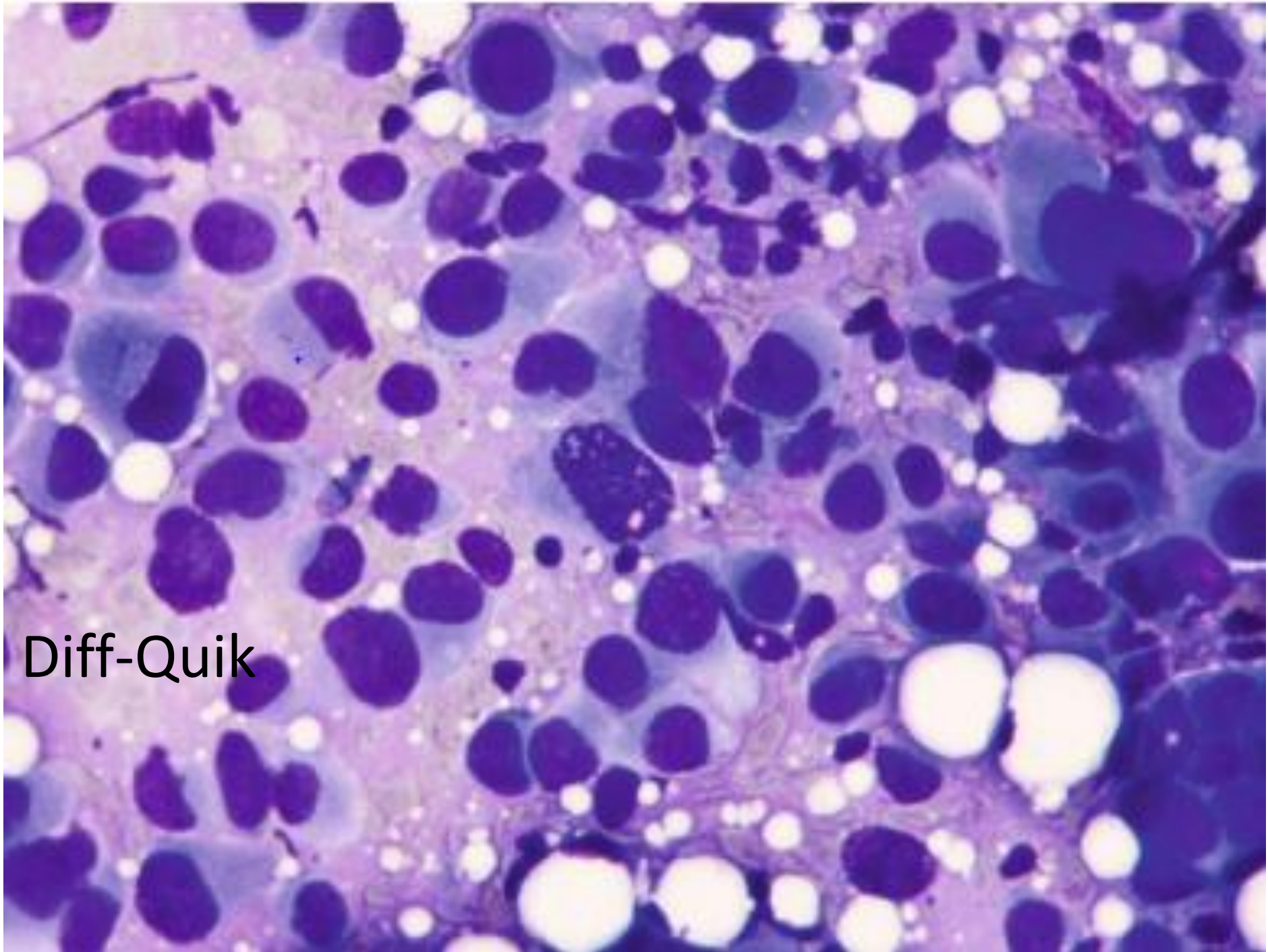
V ugly

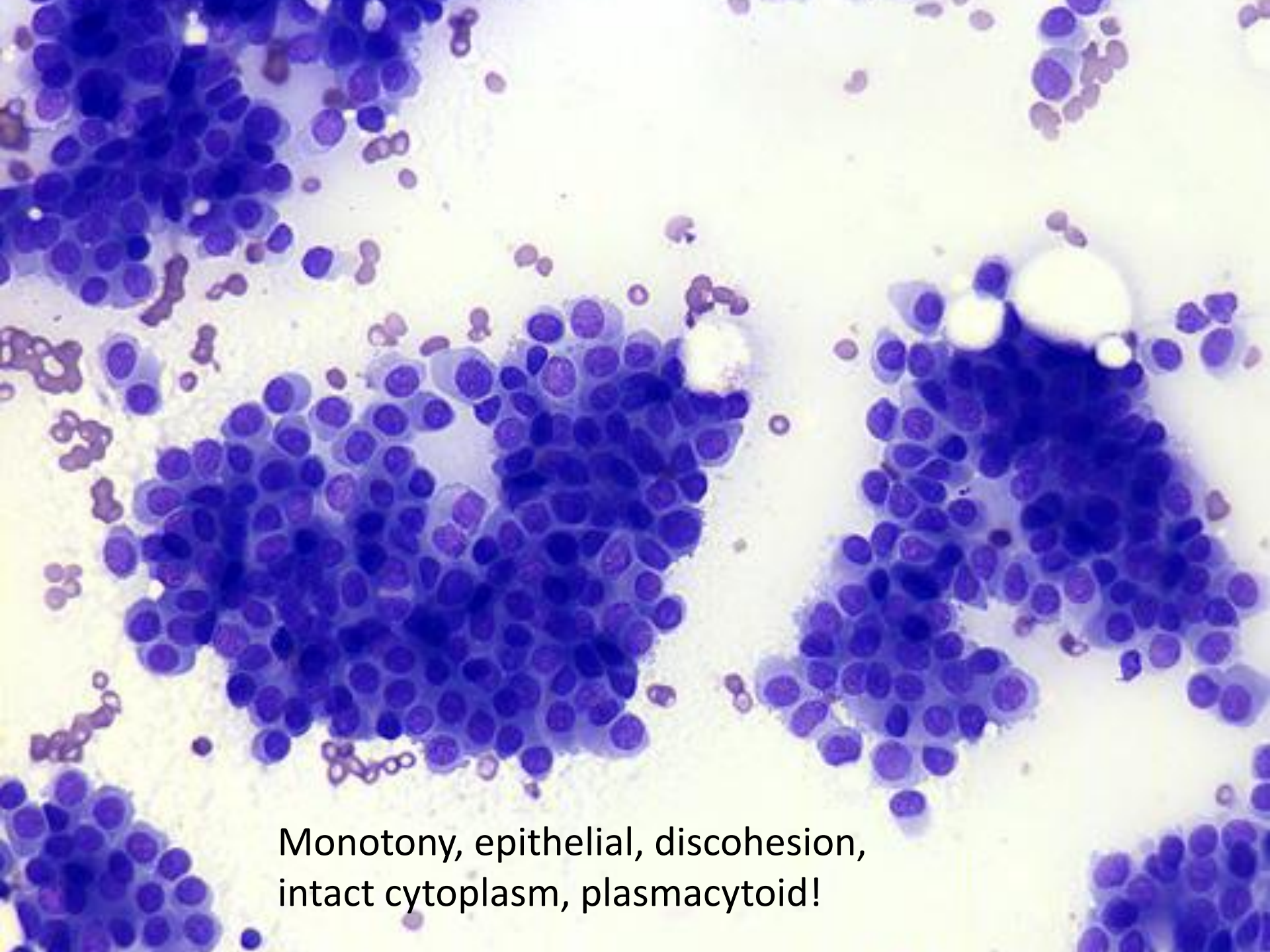
HOLOGIC



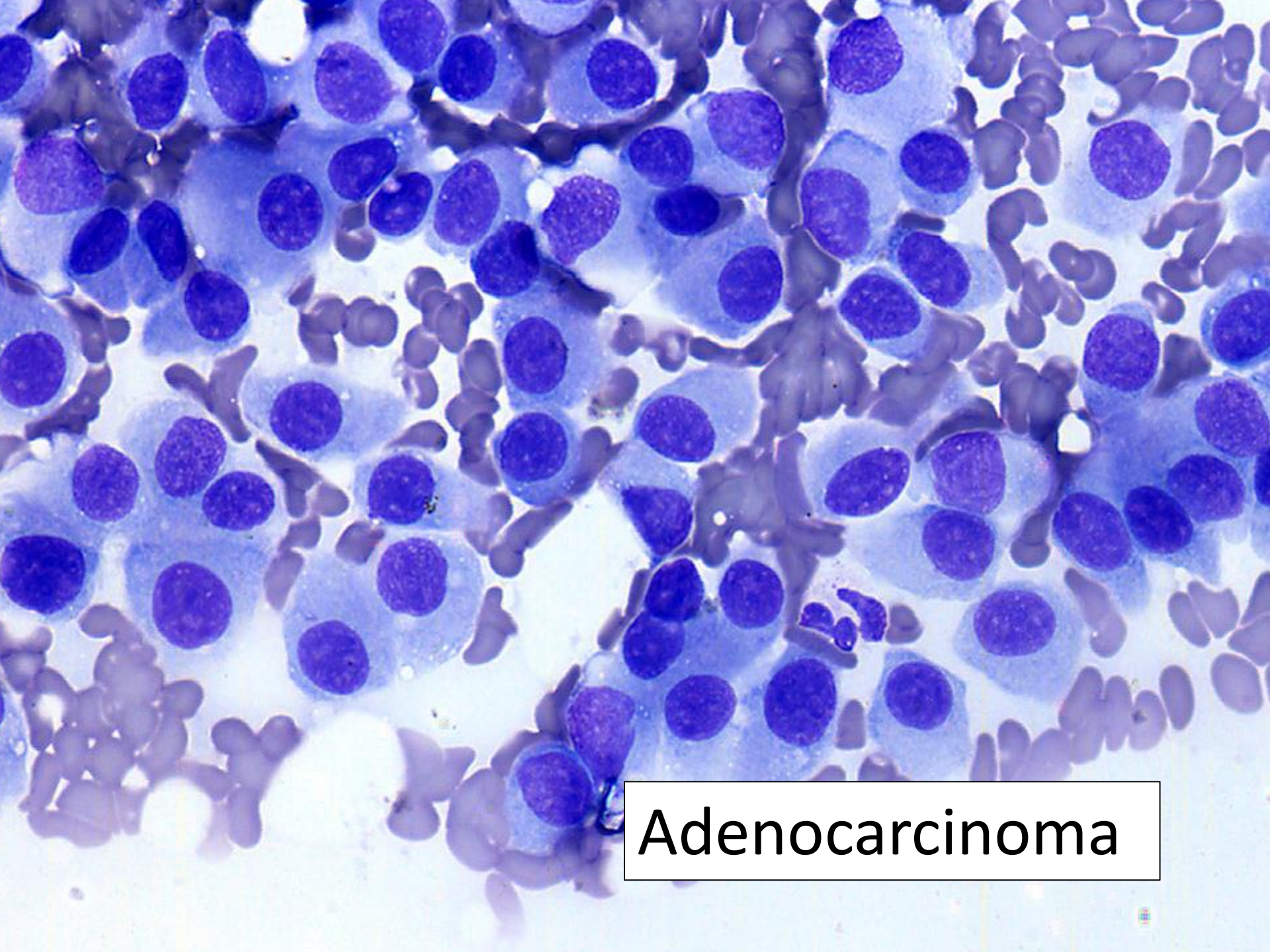
Ugly

Diff-Quik

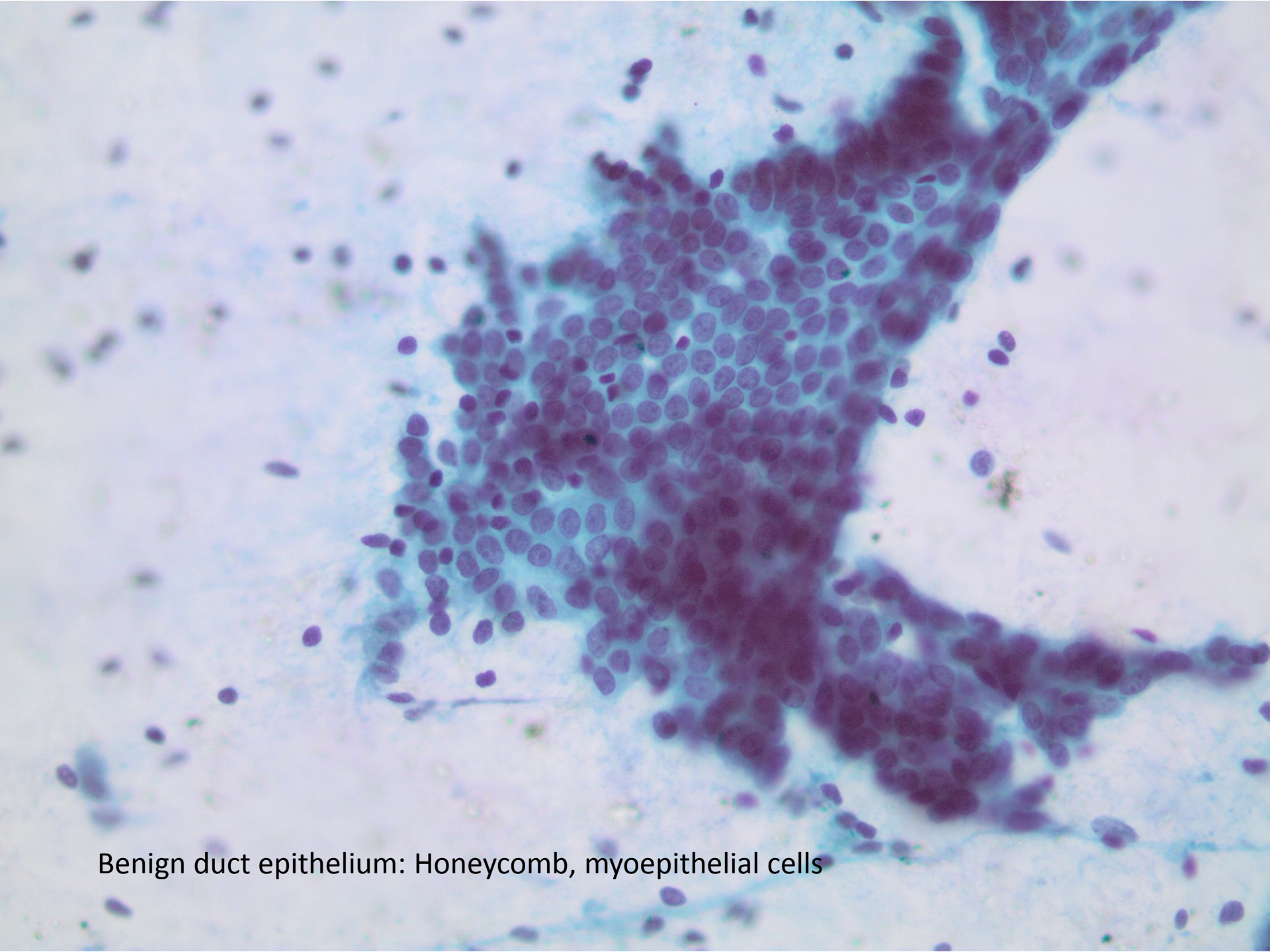




Monotony, epithelial, discohesion,  
intact cytoplasm, plasmacytoid!



Adenocarcinoma



Benign duct epithelium: Honeycomb, myoepithelial cells

# Criteria for malignancy

1. ↑ ↑ cellularity
2. Discohesion: Loosely cohesive epithelial cells + individual tumor cells with intact cytoplasm
3. Variable degree of malignant cytologic features (ugliness)
  - Anisonucleosis, irregular nuclear borders, ↑N/C ratio, hyperchromasia, coarsely granular chromatin, prominent nucleoli
  - No bipolar naked nuclei

# Tumor grade

- HISTOLOGY

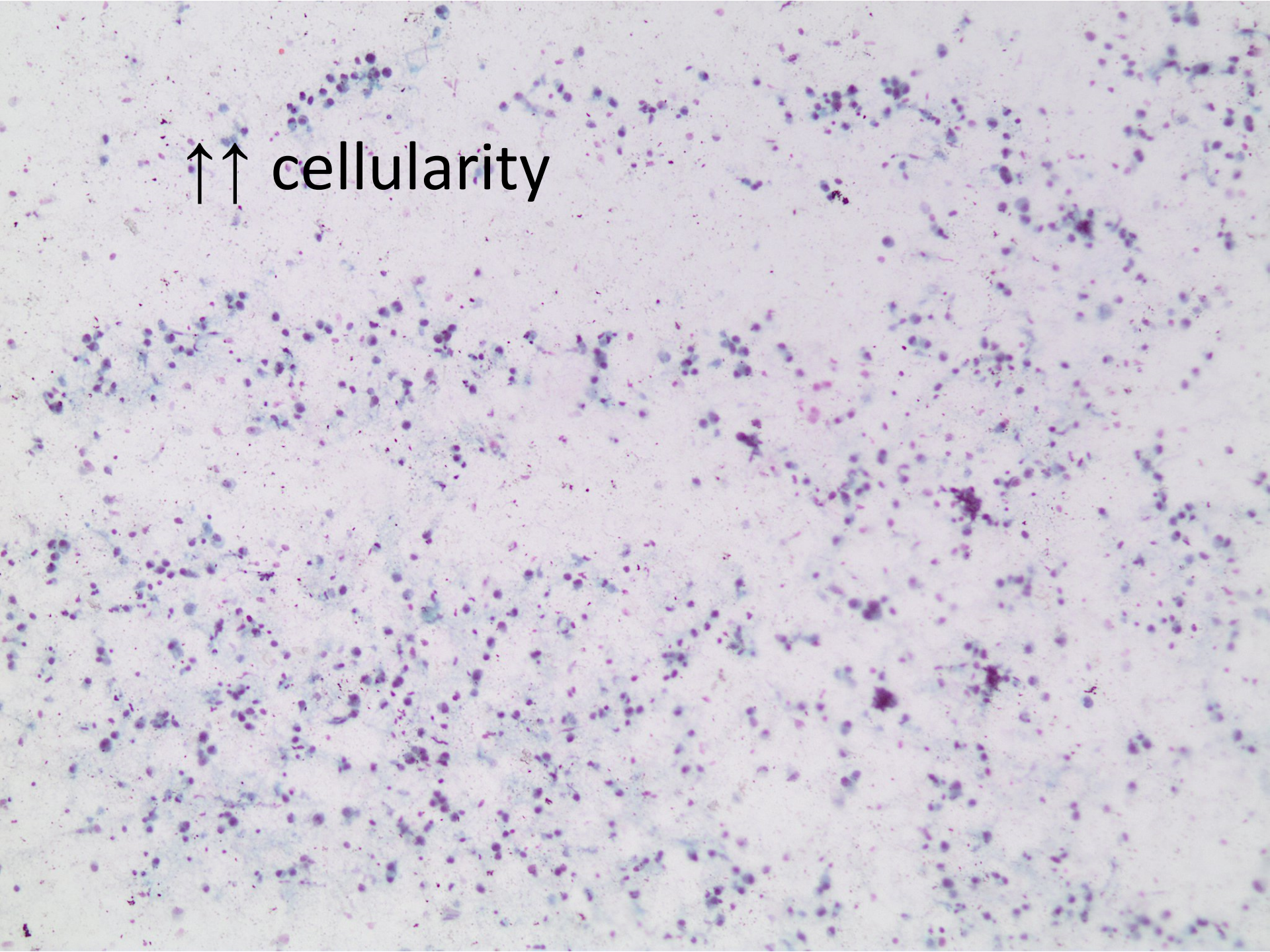
- Glands
- Nuclei
- Mitosis

- CYTOLOGY

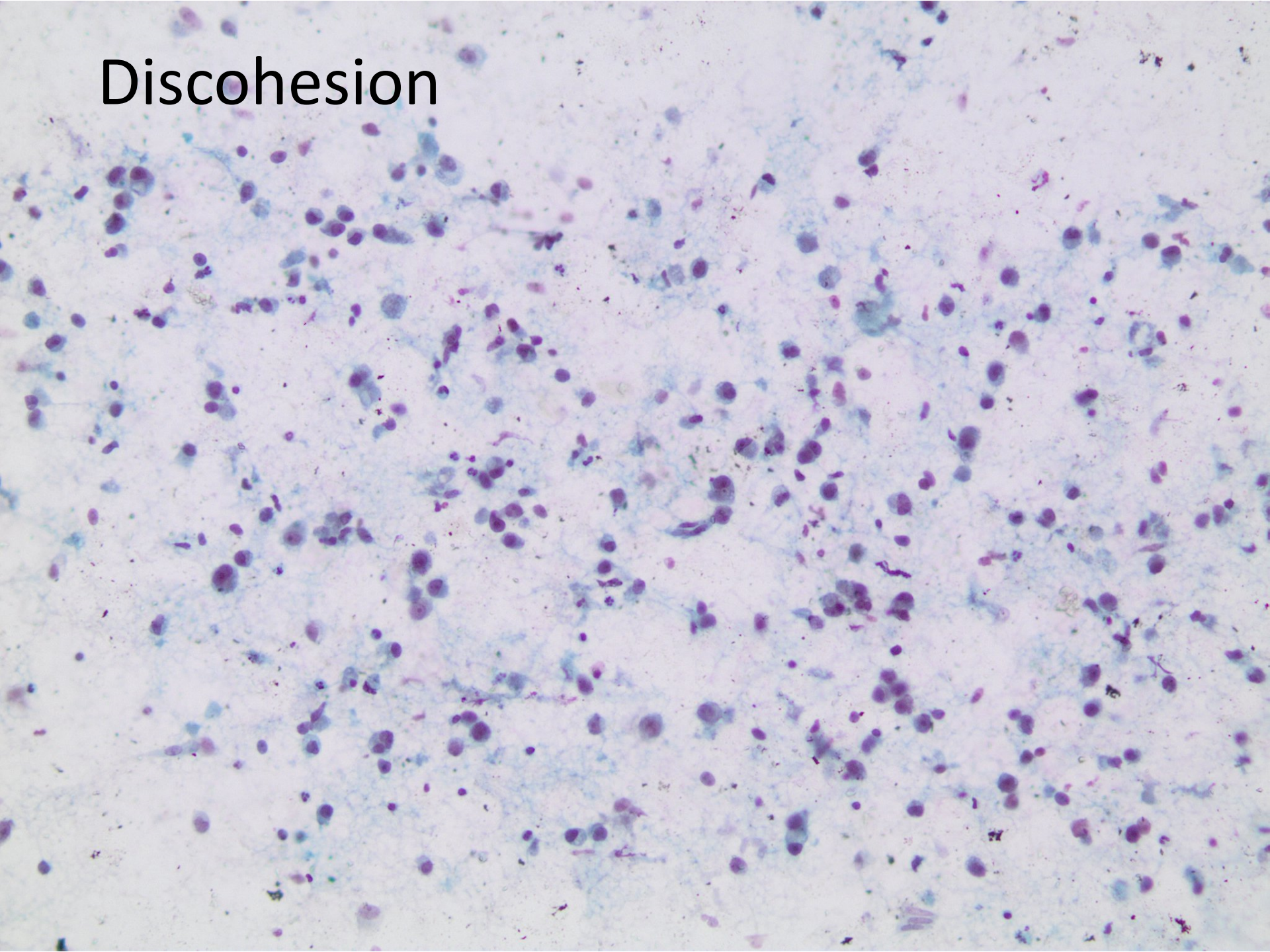
- Nuclei
  - Size
  - Membrane
  - Chromatin
  - Nucleoli

*Nuclear grade 1-3  
Good correlation with histologic  
grade*

↑↑ cellularity



# Discohesion



A microscopic image showing a field of cells stained with hematoxylin and eosin (H&E). The cells are arranged in a somewhat disorganized pattern, with many having large, round, hyperchromatic nuclei. The cytoplasm is pale, and the overall appearance is consistent with a low-grade adenocarcinoma. The background is a light, pinkish-purple hue.

Not v ugly

**ADENOCARCINOMA, LOW NUCLEAR GRADE**



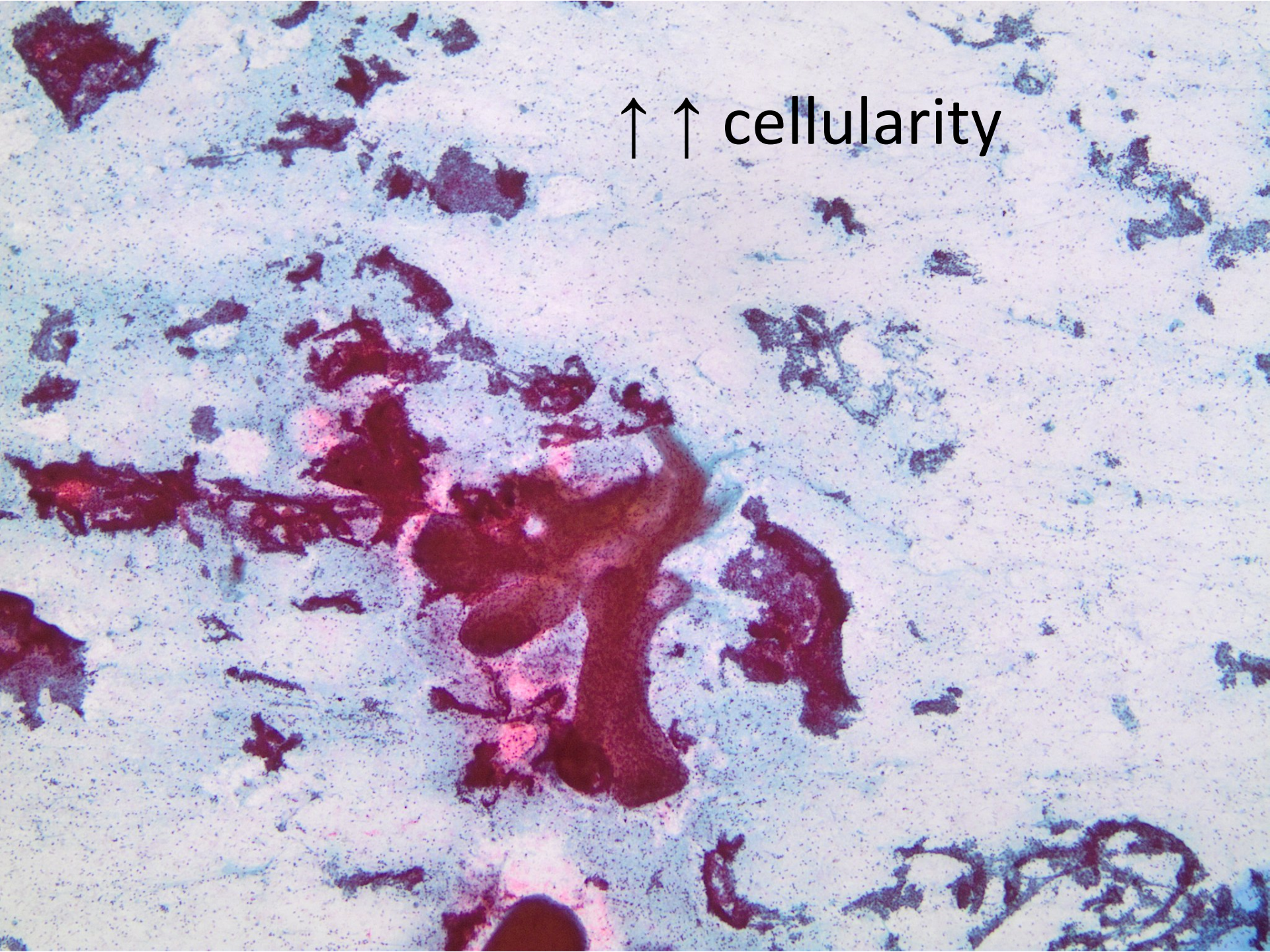
# C2 Obviously Benign

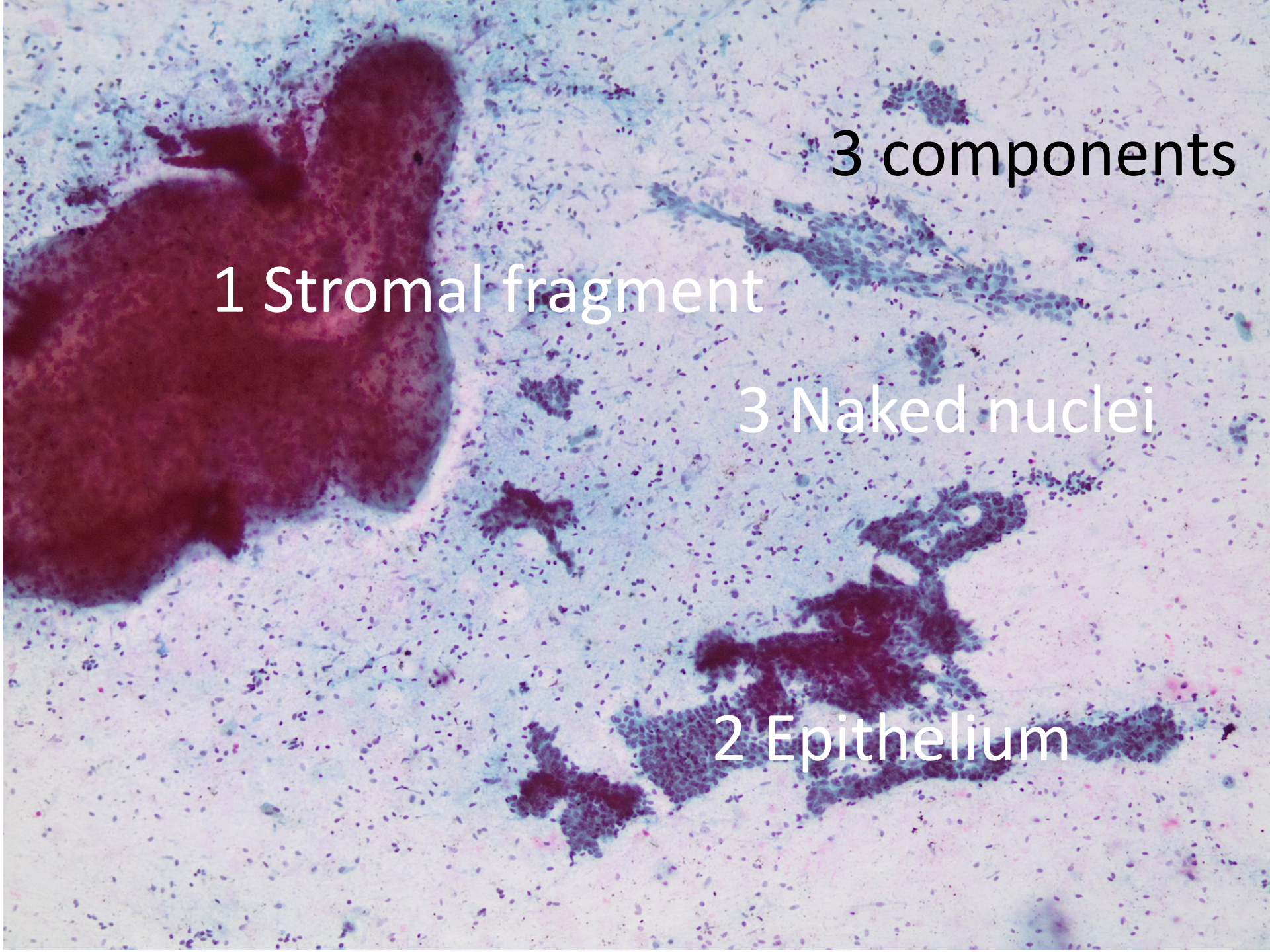
- FNA: Adequate and representative
  - Fibroadenoma
  - FCC (cysts)
  - Abscess
  - Fat necrosis

# Case

- History: 28 F, 3cm well circumscribed egg-like movable mass,
- FNA Feel: Rubbery

↑ ↑ cellularity





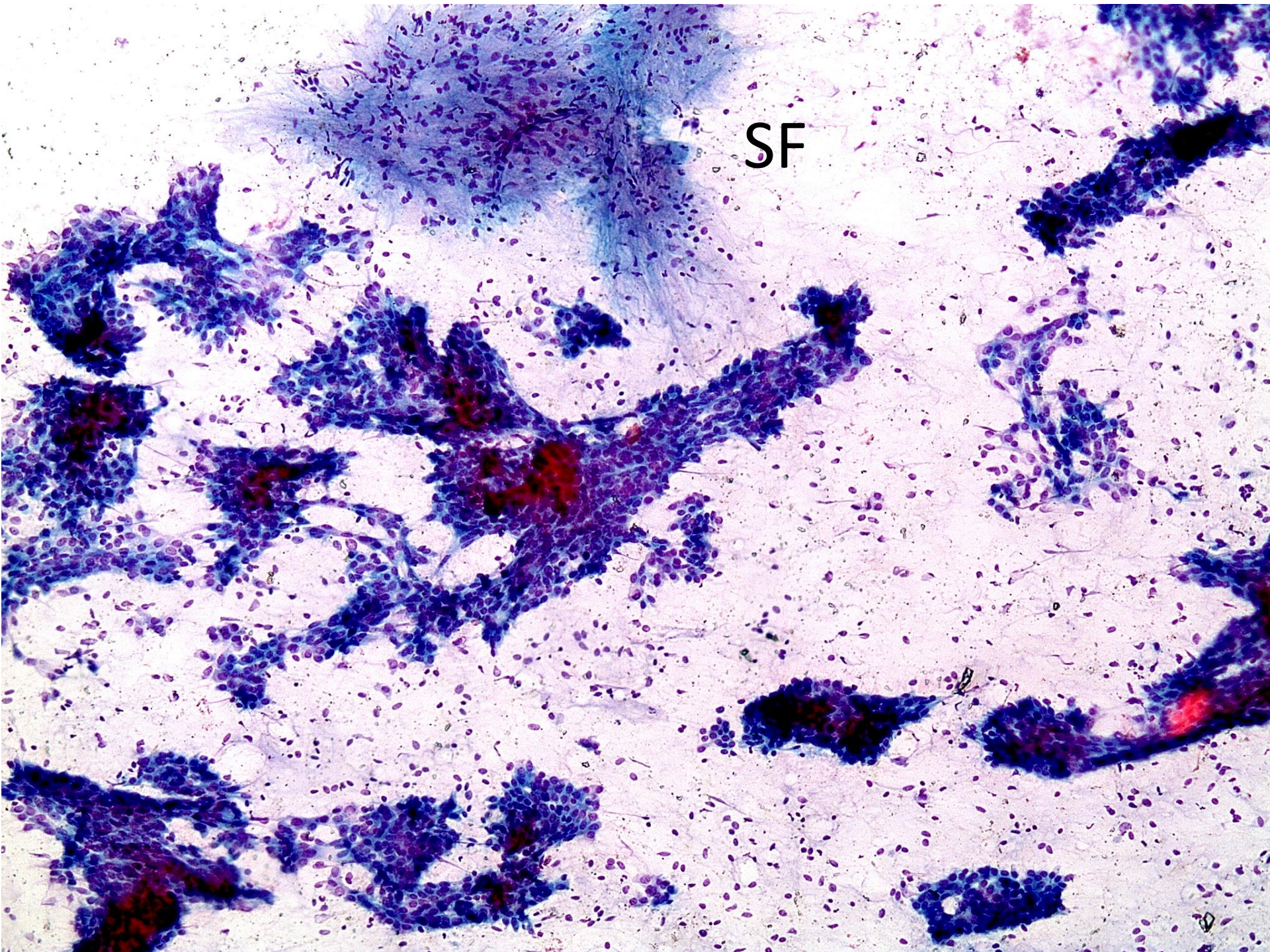
3 components

1 Stromal fragment

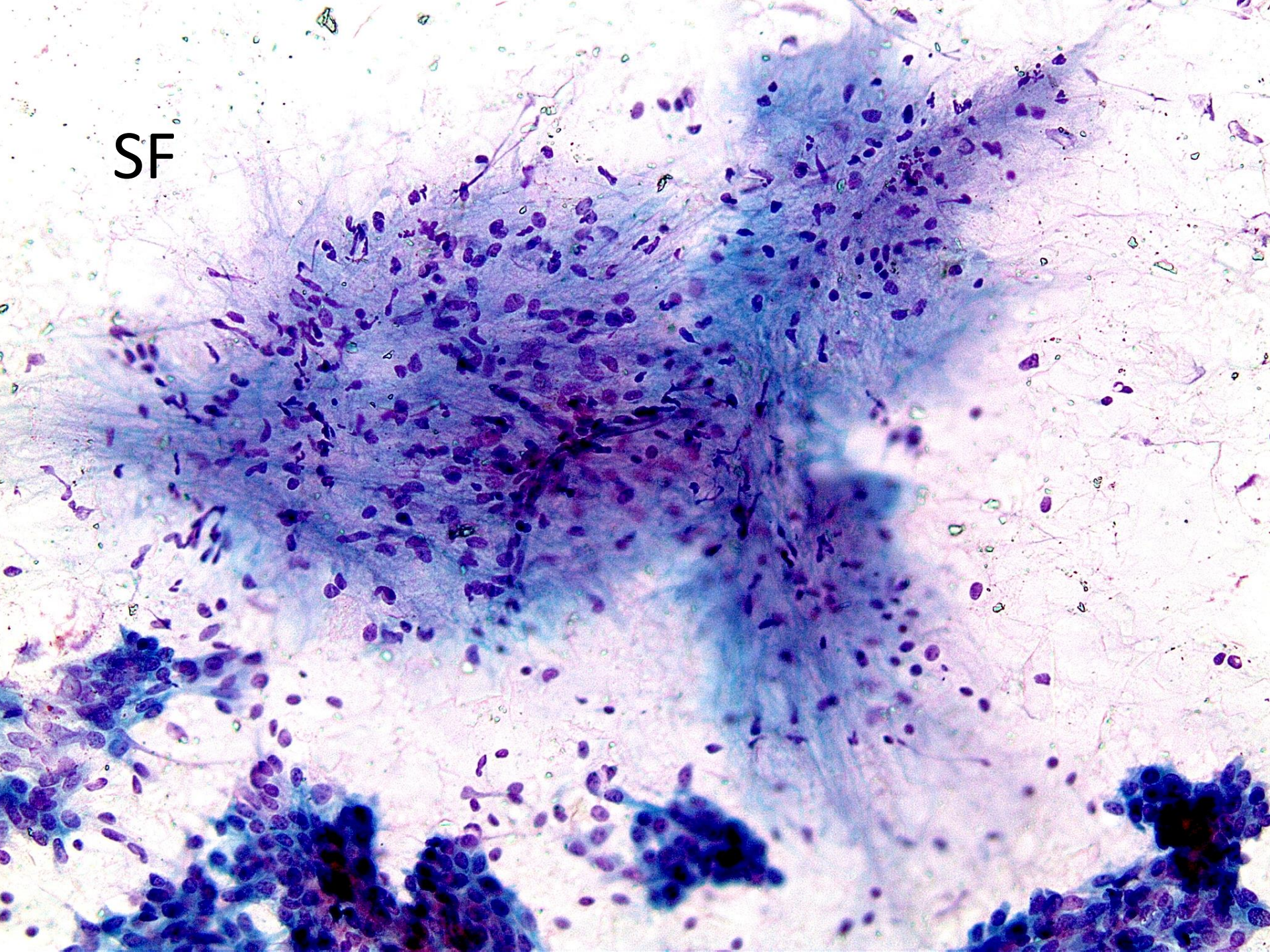
3 Naked nuclei

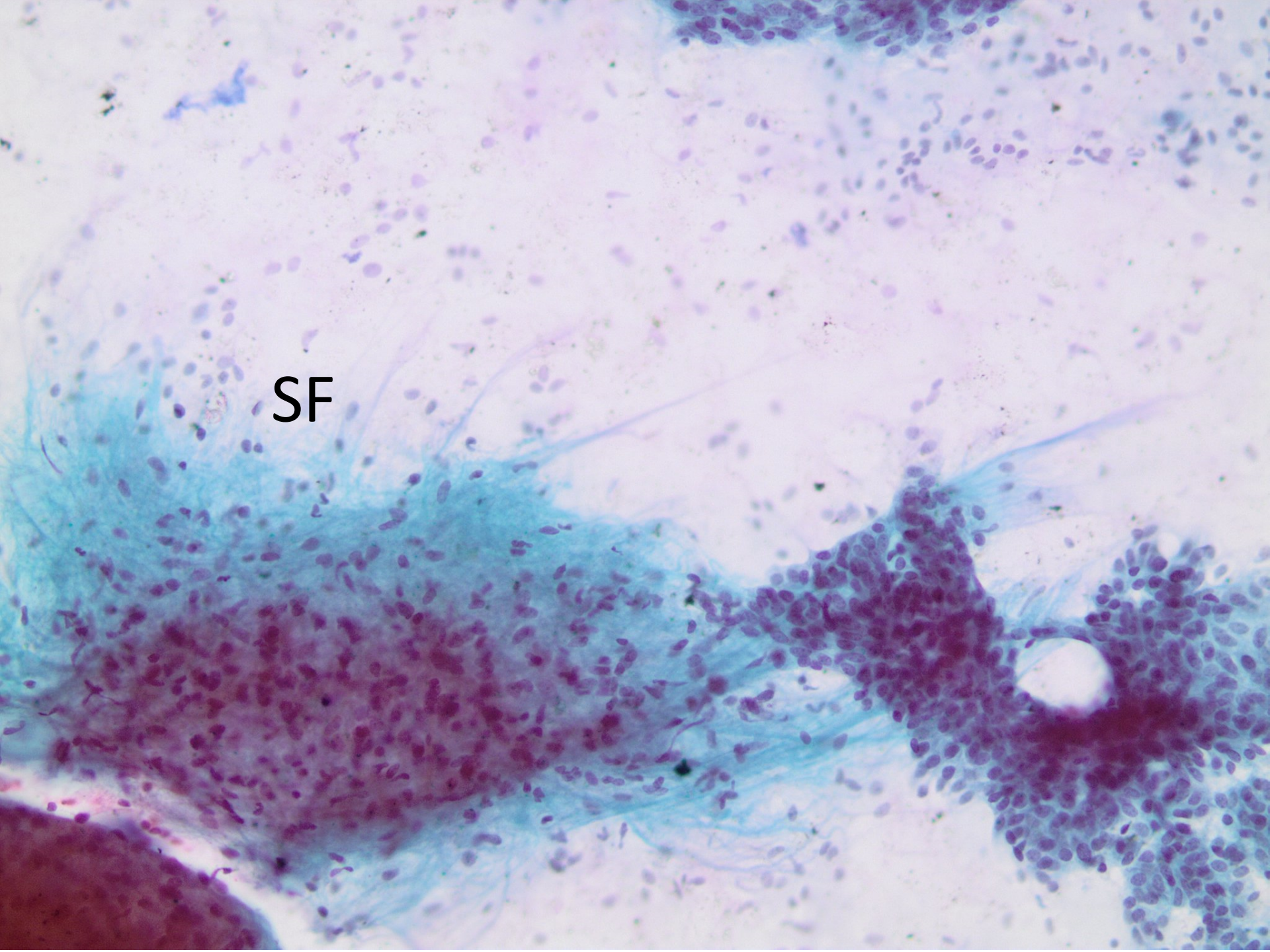
2 Epithelium

SF

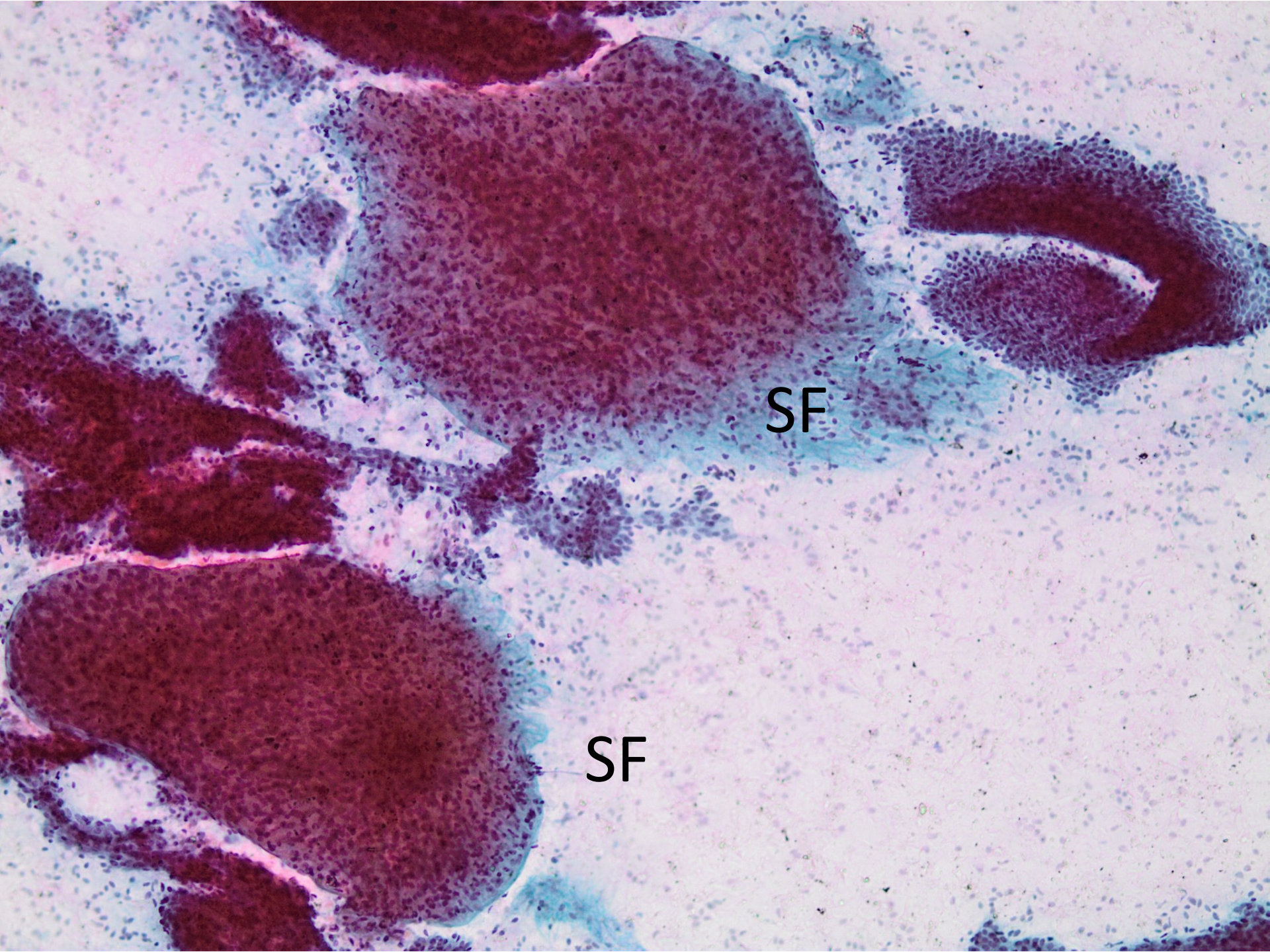


SF



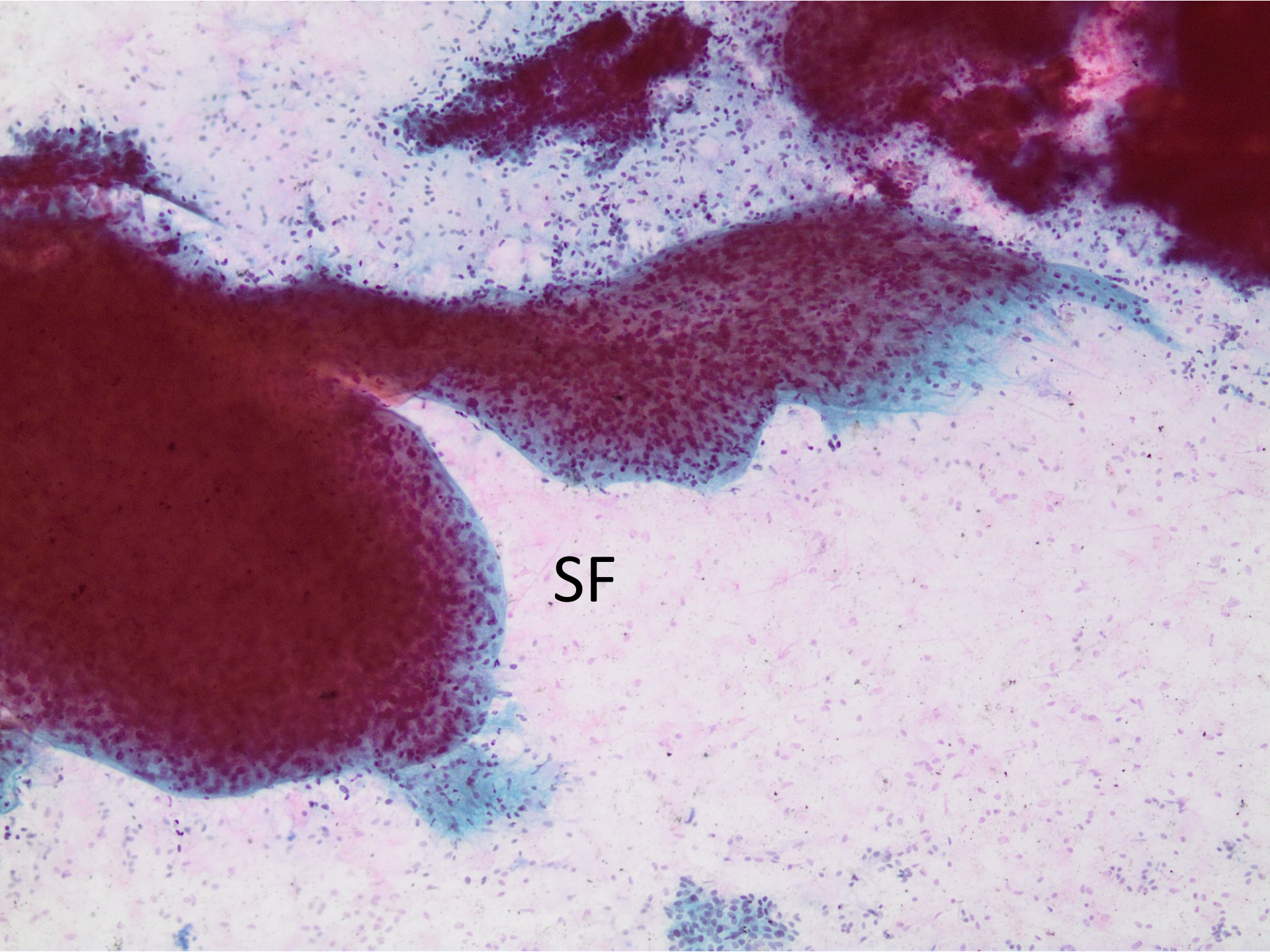


SF



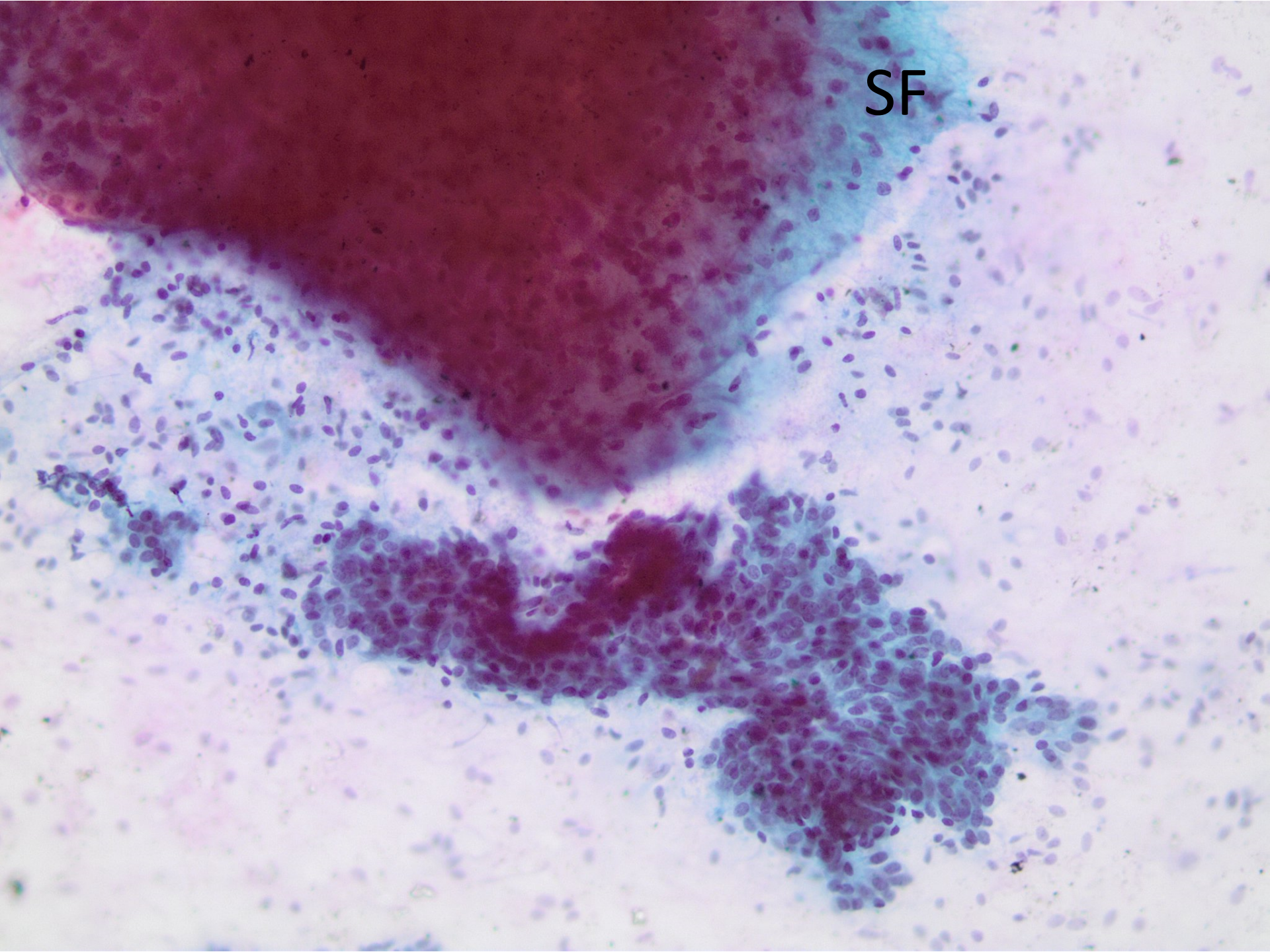
SF

SF

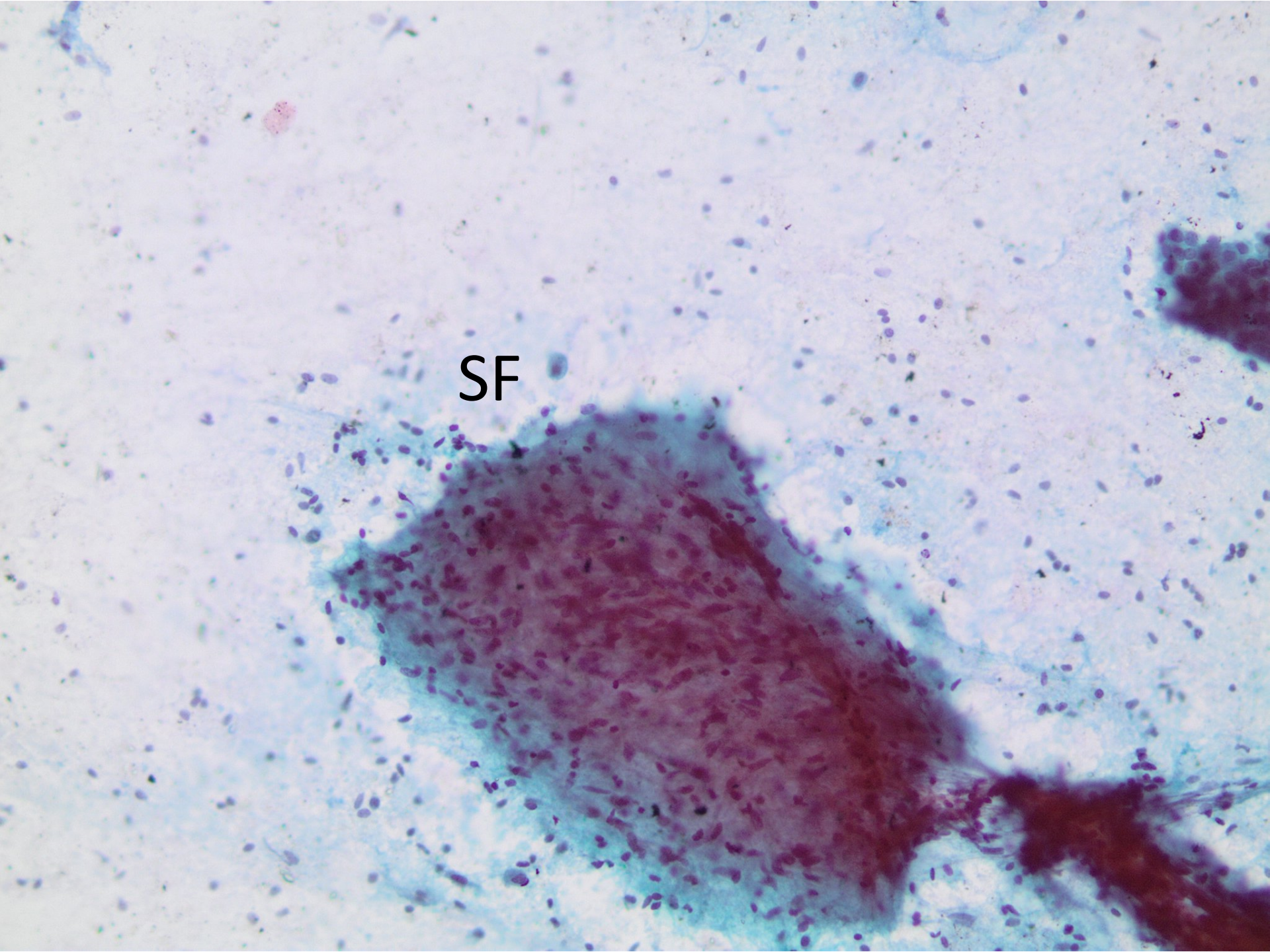


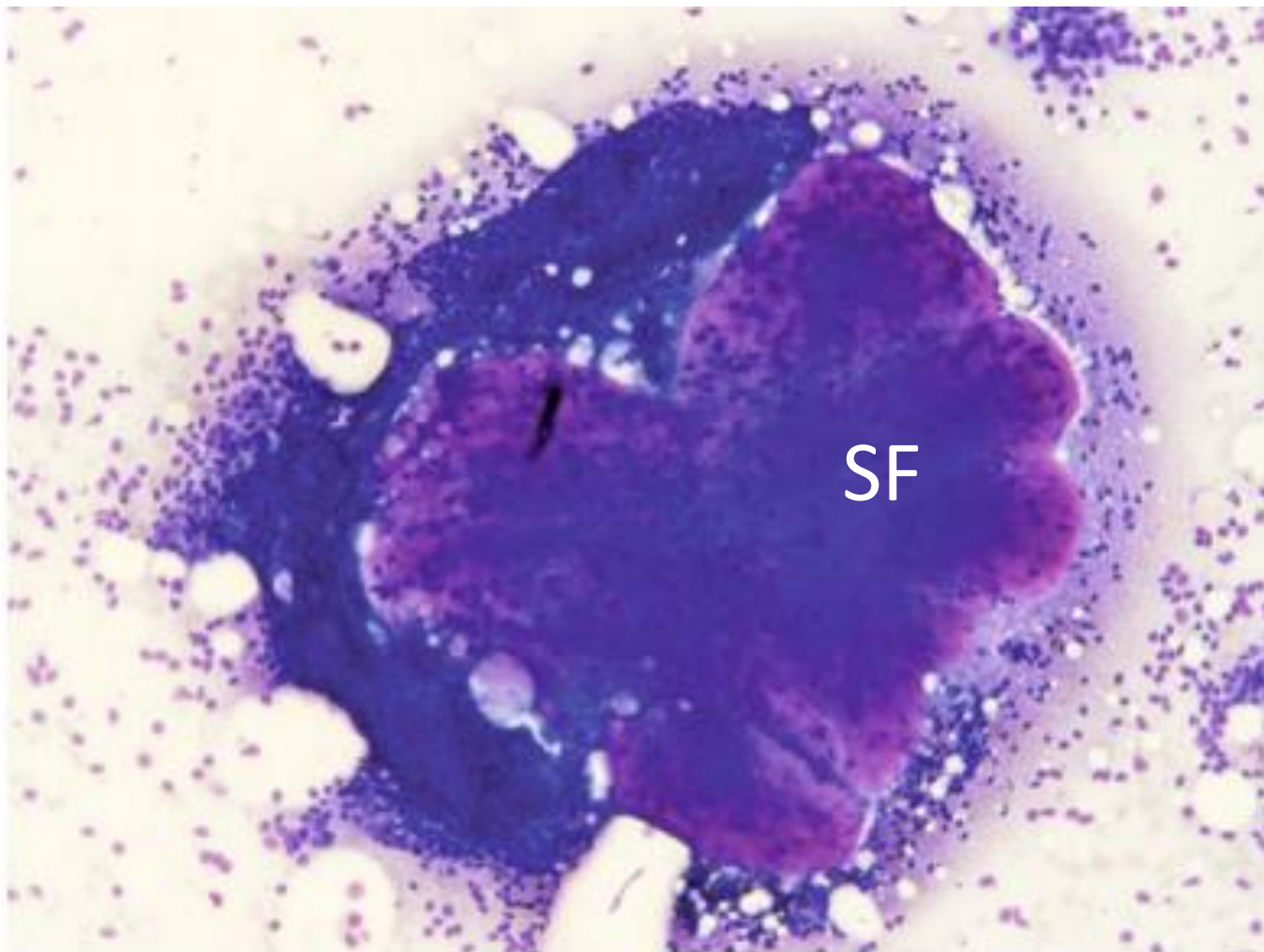
SF

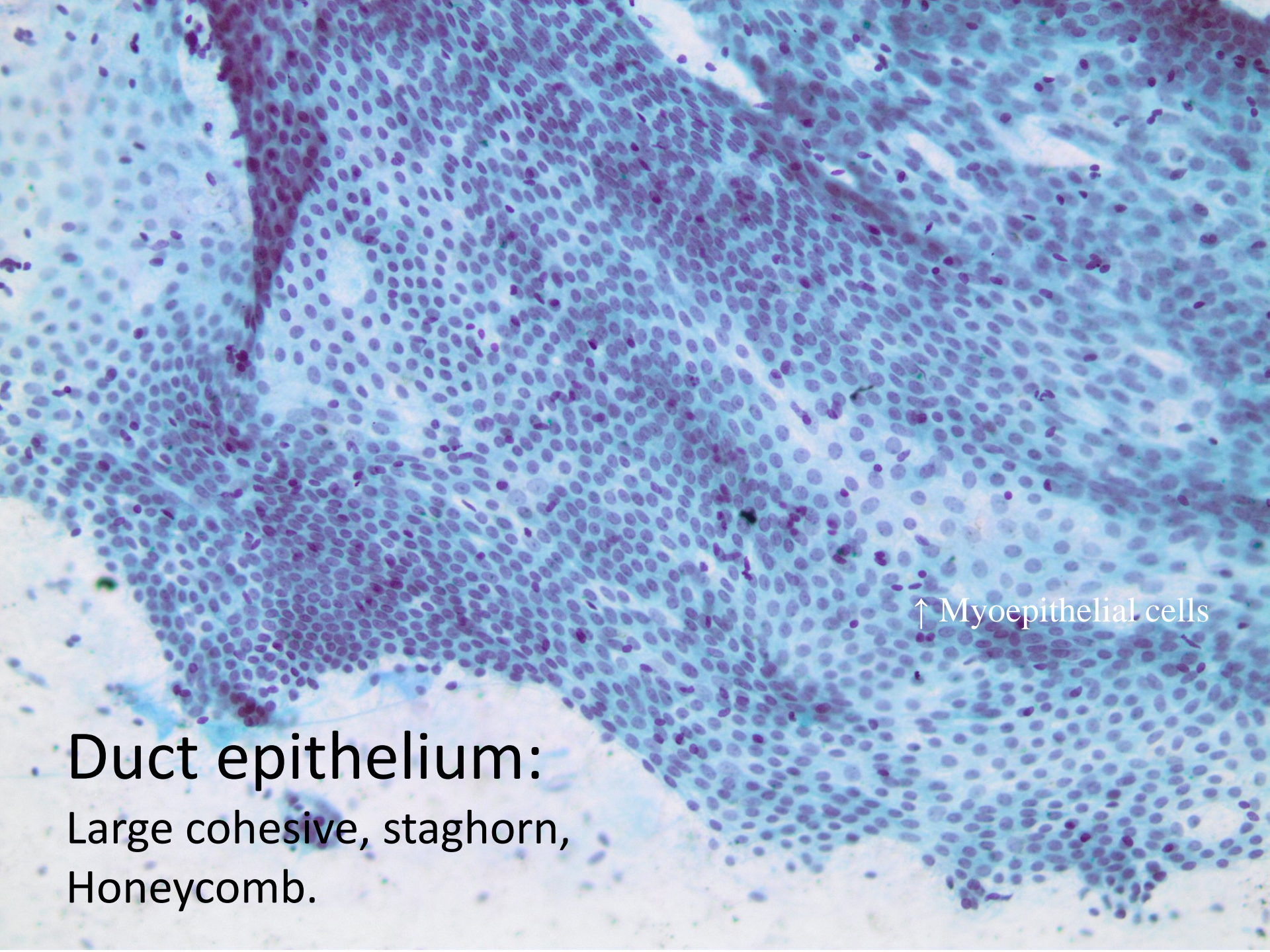
SF



SF





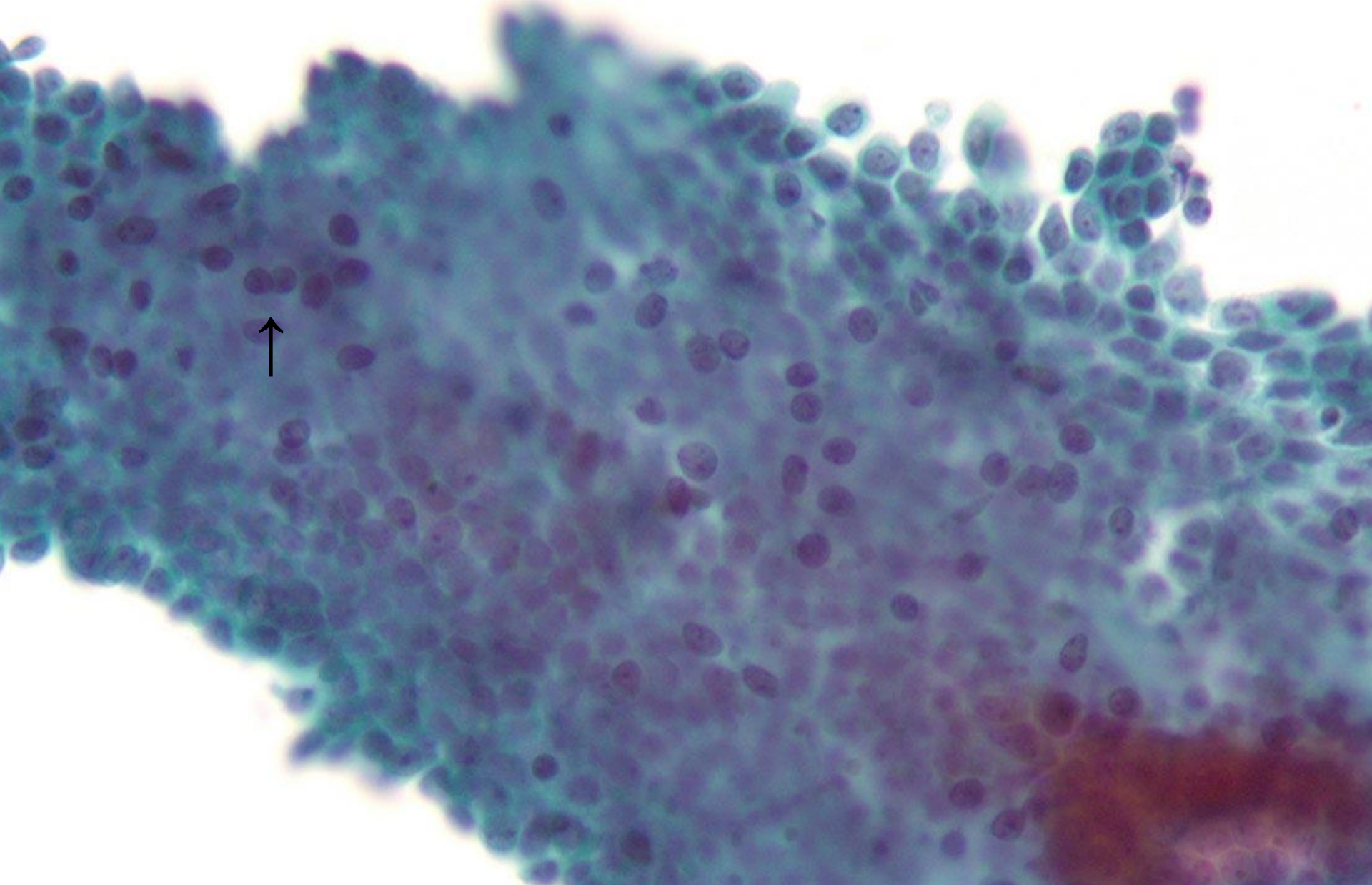


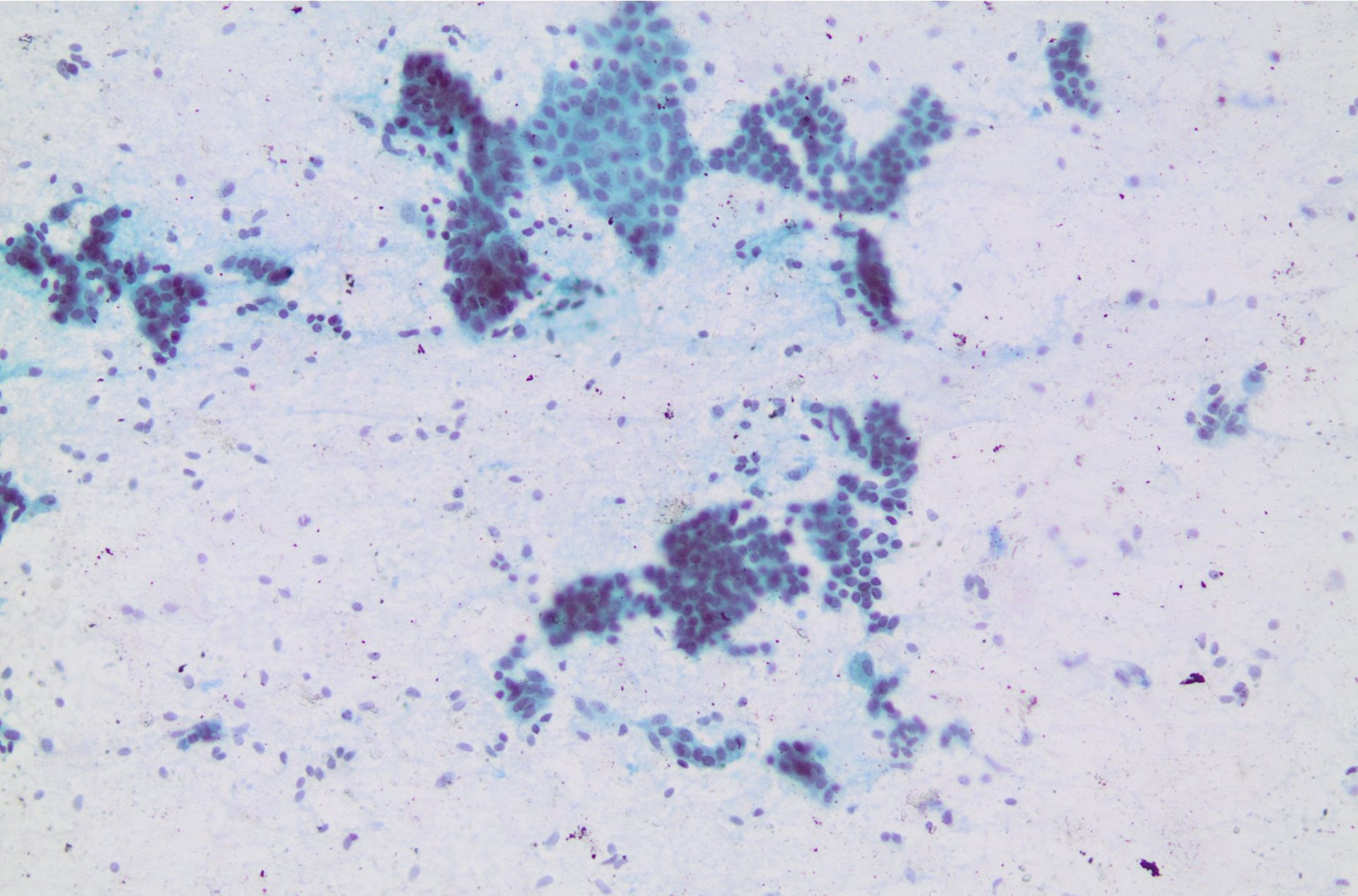
↑ Myoepithelial cells

## Duct epithelium:

Large cohesive, staghorn,  
Honeycomb.

Benign duct epithelium with myoepithelial cells



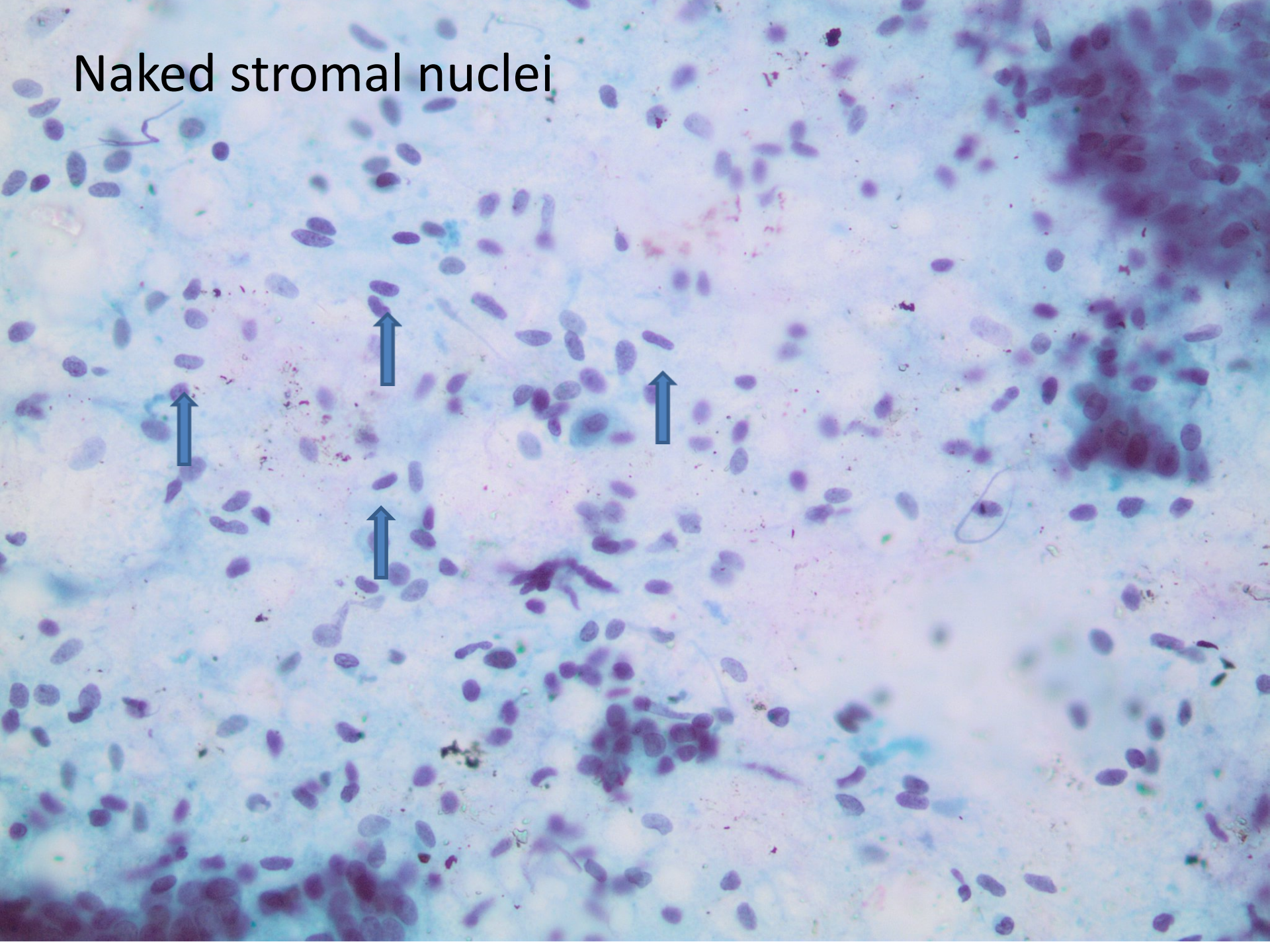


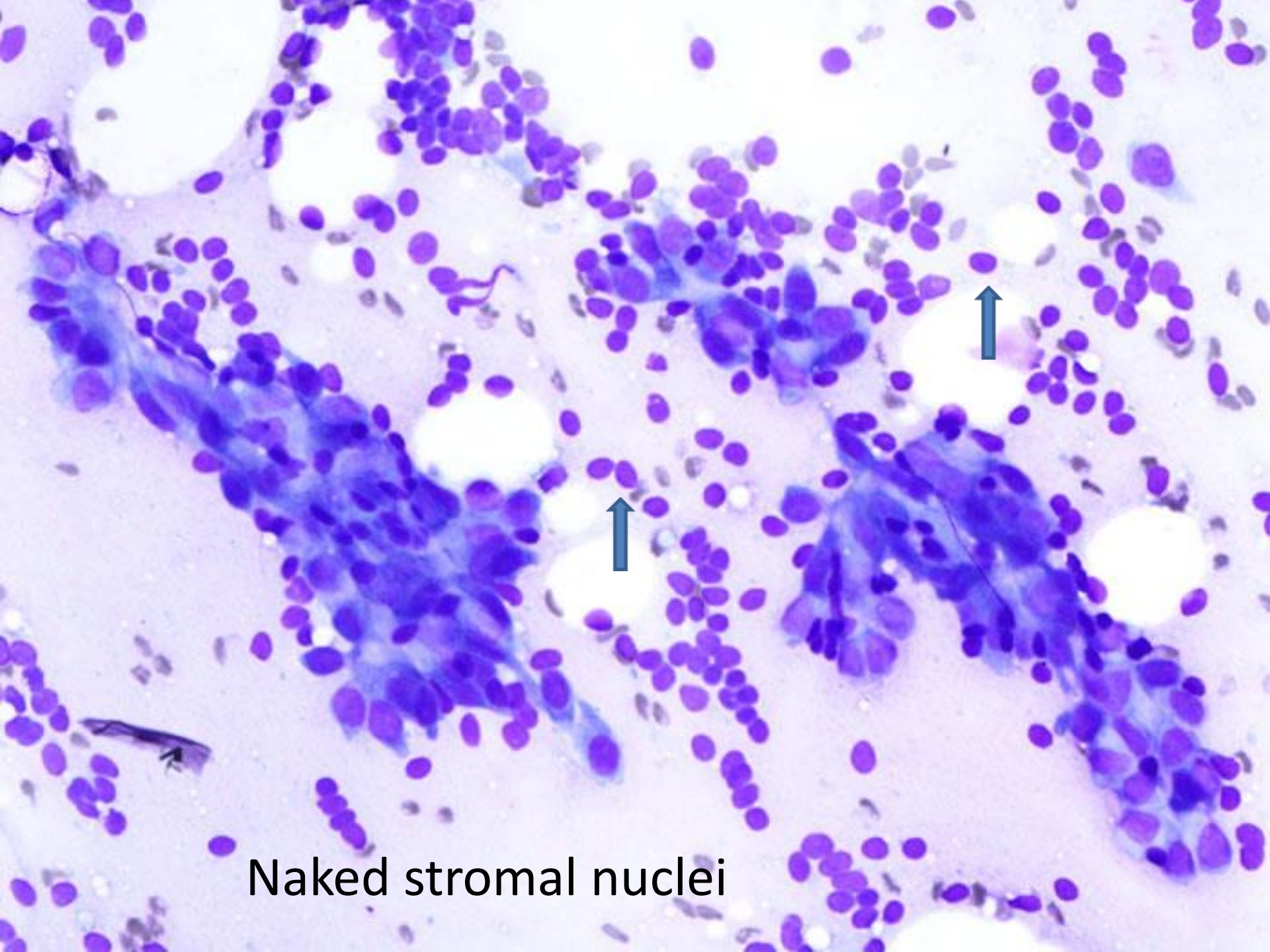
Ignore scattered discohesive epithelial cells

Naked stromal nuclei



Naked stromal nuclei



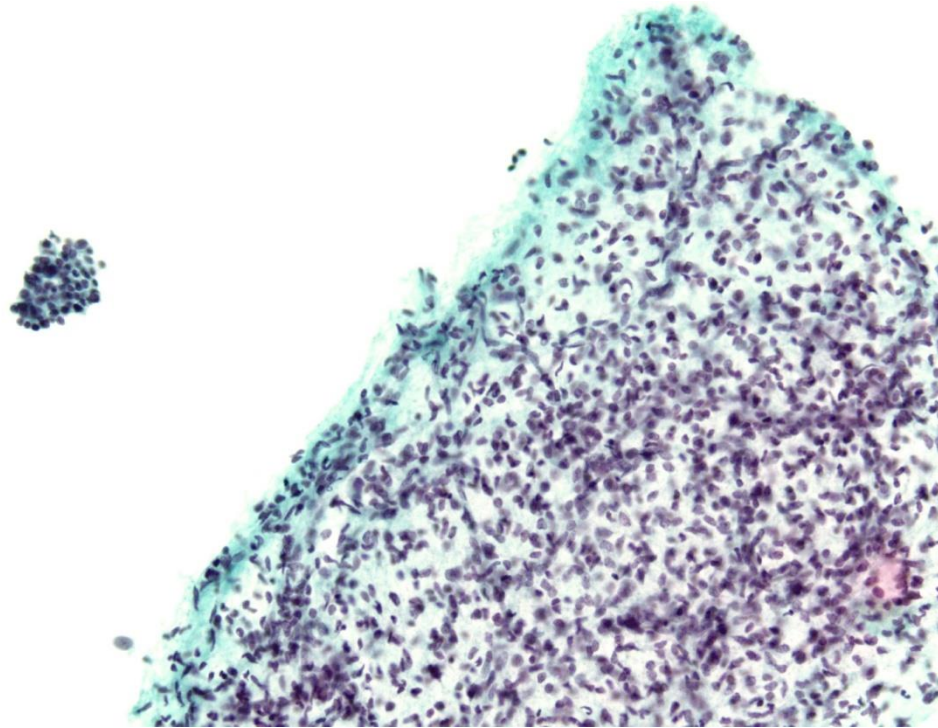


Naked stromal nuclei

# Fibroadenoma

- Smears (pattern recognition)
  - Very cellular
  - 3 components
    - Stromal fragments
    - Staghorn epithelial cohesive honeycombed duct cells
    - Numerous myoepithelial cells (naked stromal nuclei)

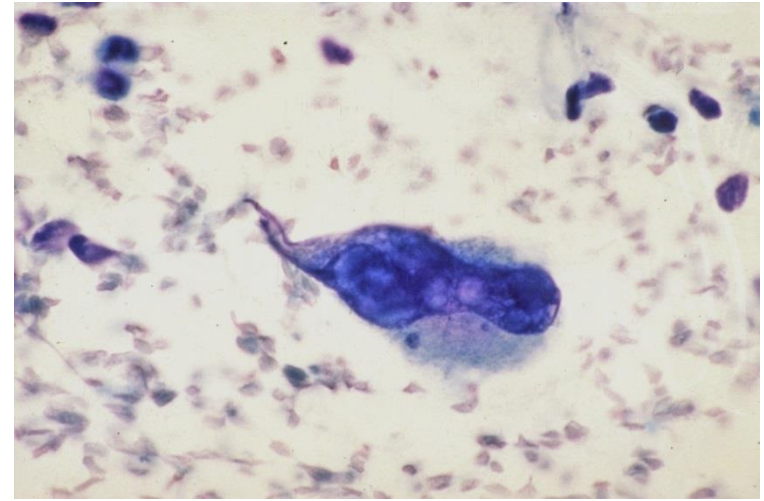
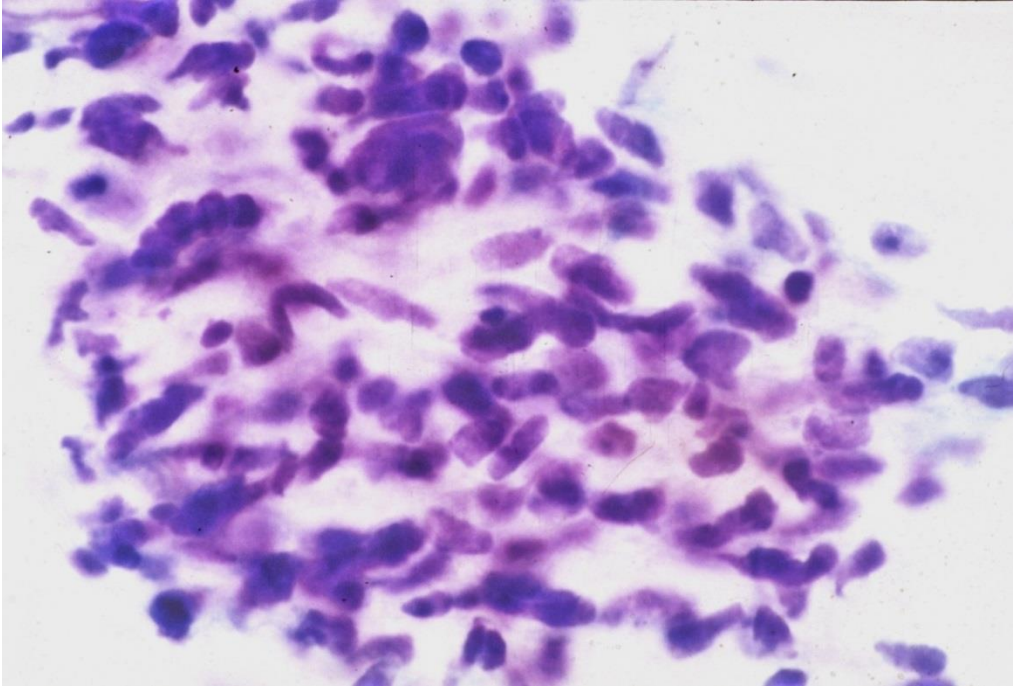
# Cellular stromal fragments?



# Phyllodes Tumor

- Cellular stromal fragments
  - Feature of PT
  - Also seen in FA (smearing artifact)
  - Not a reliable distinguishing feature FA/PT
  - Blood vessels traversing CSF, feature PT
  - Significant nuclear atypia and mitosis → Malignant PT
- Associated intraductal hyperplasia → Misdiagnosed AdenoCa
- > 4cm with rapid growth → PT

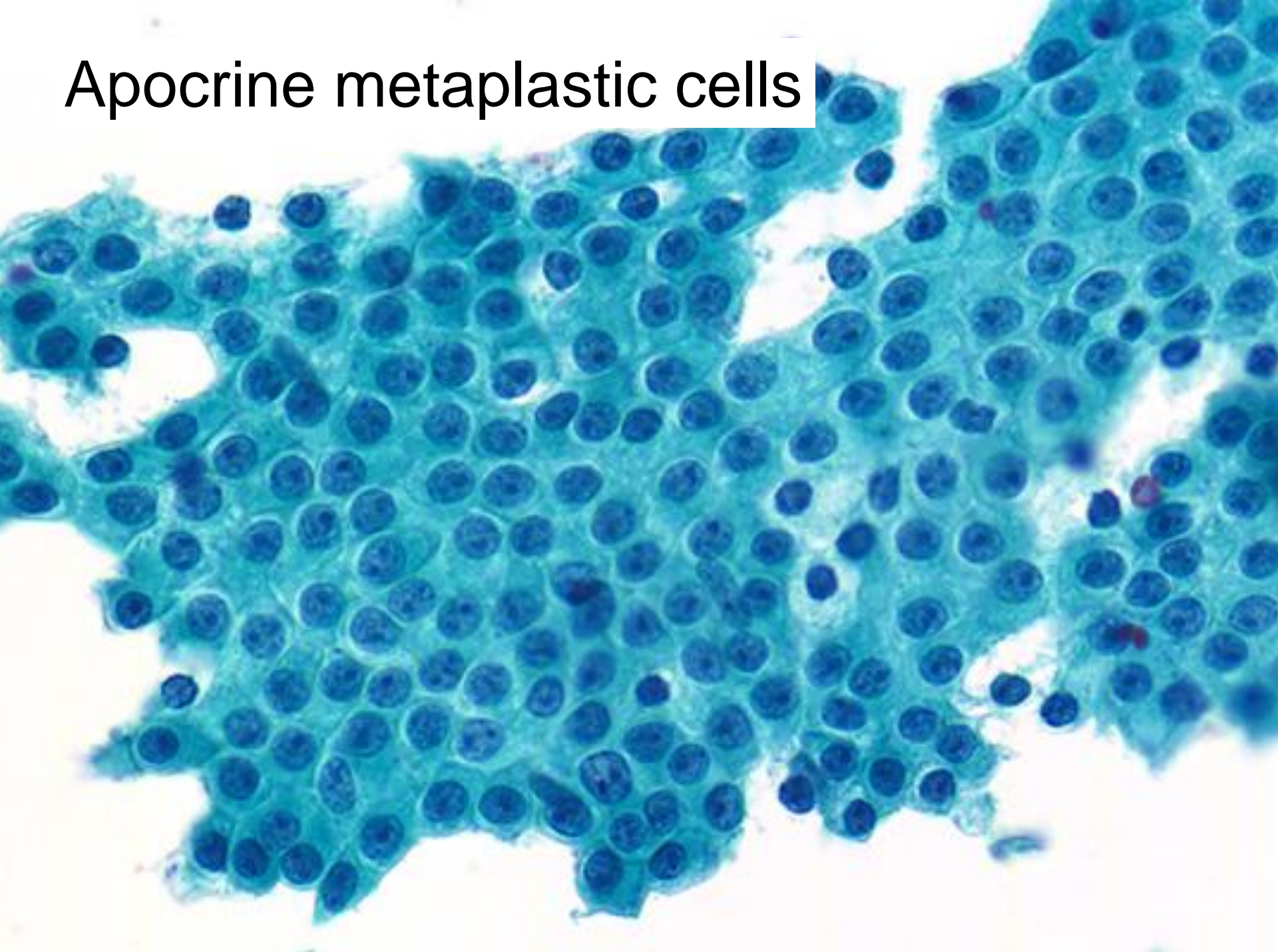
# PT malignant



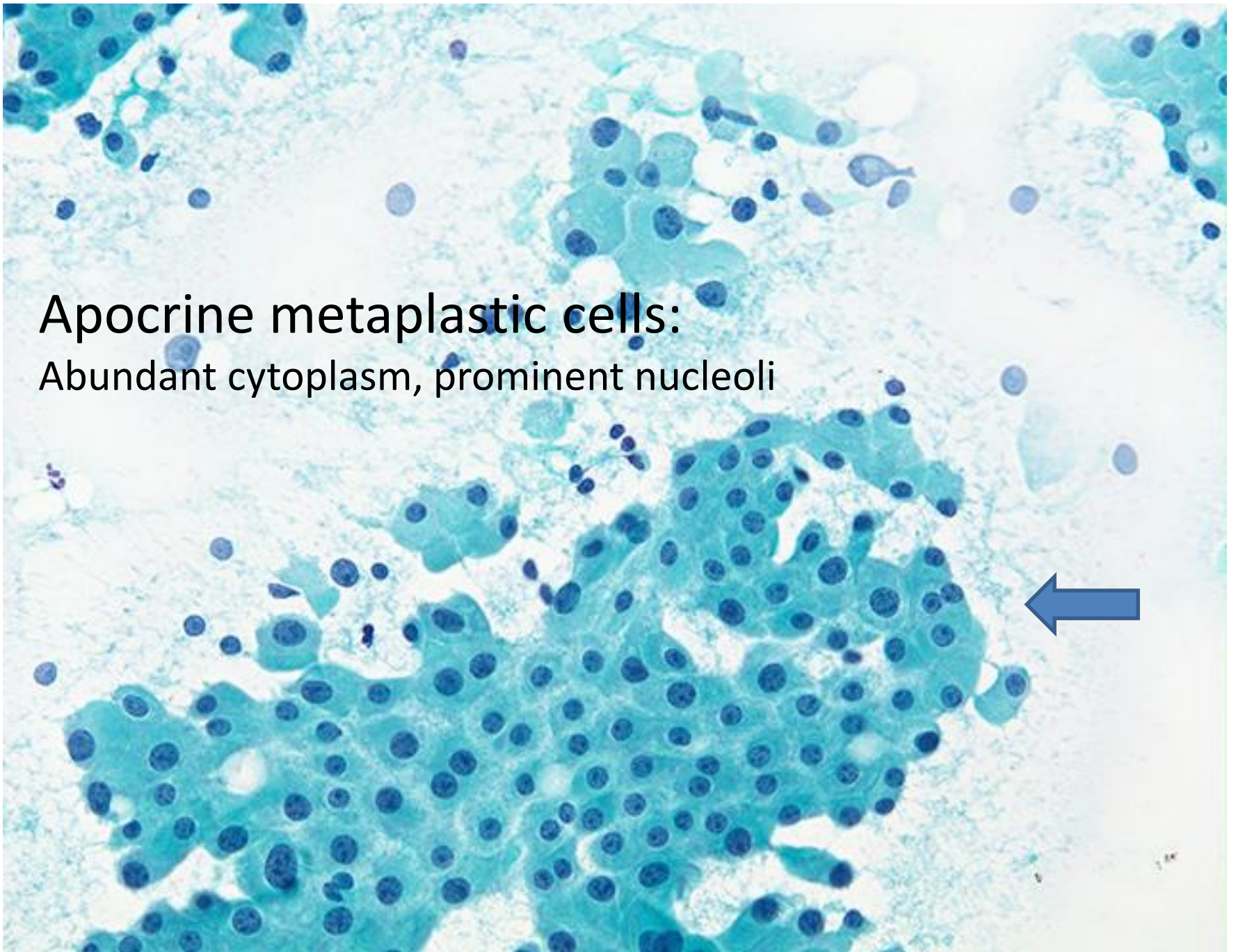
# FCC

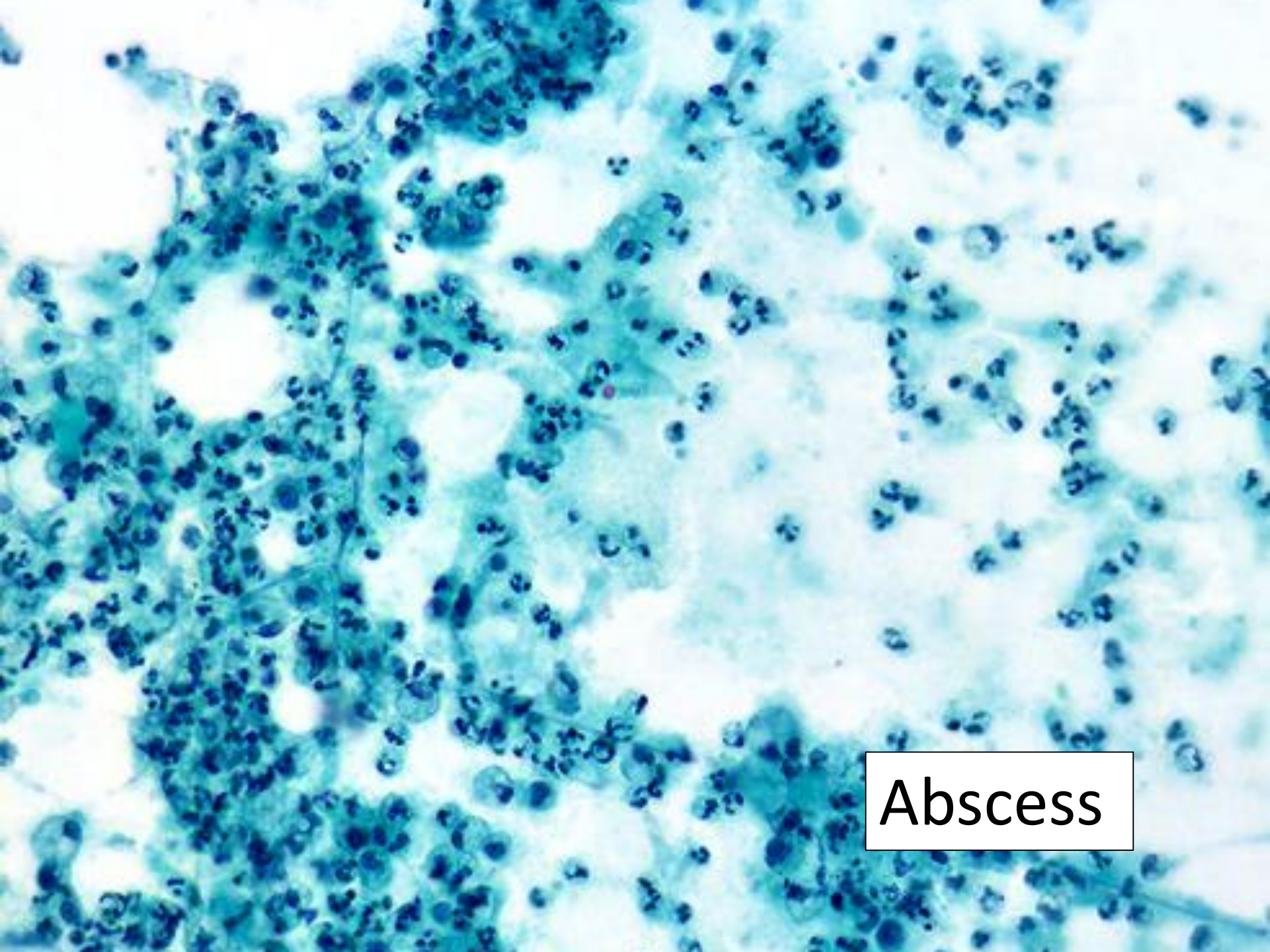
- Hypocellular
  - Benign duct epithelial cells
  - Naked nuclei
  - Apocrine metaplastic cells

# Apocrine metaplastic cells

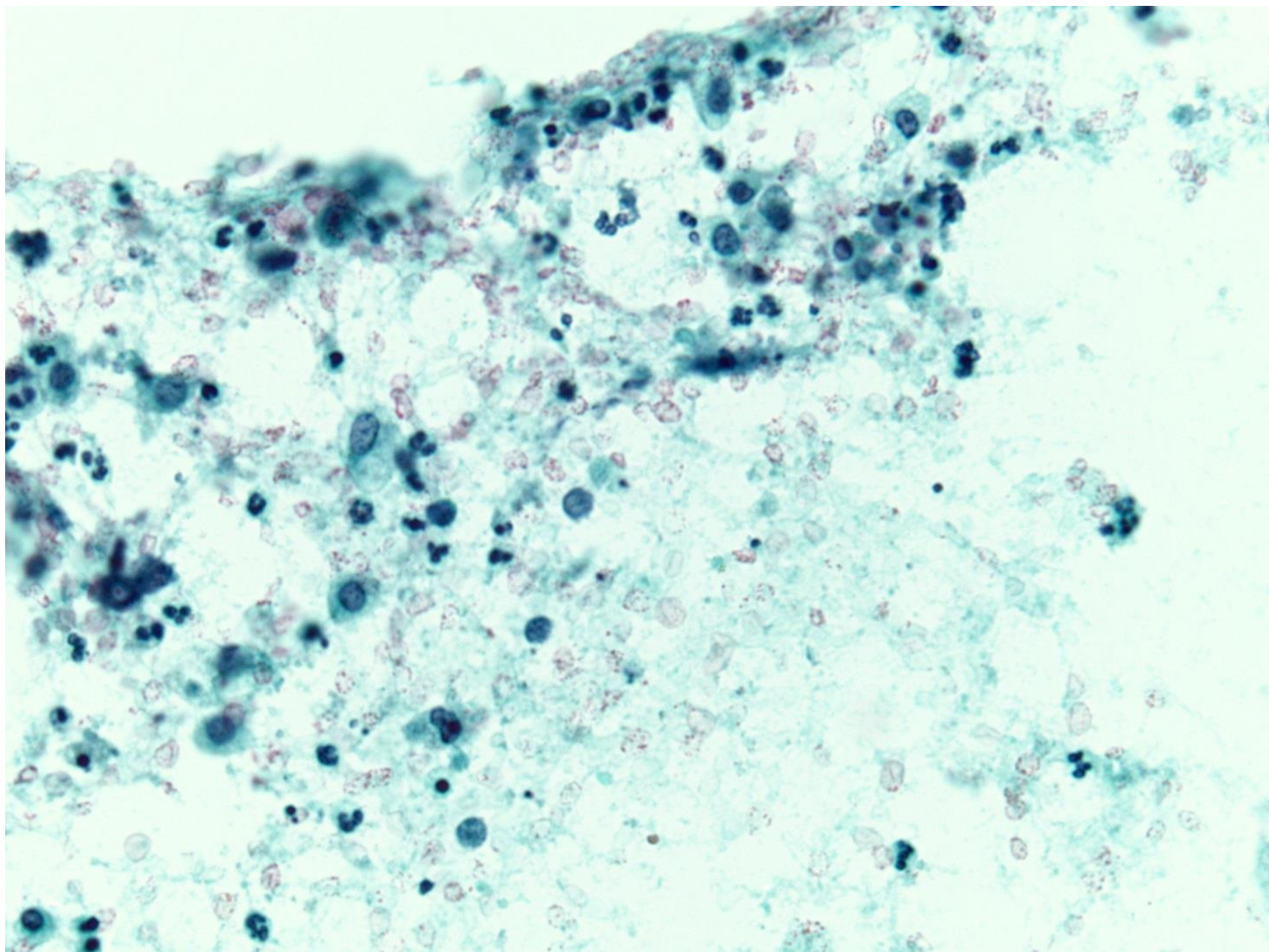


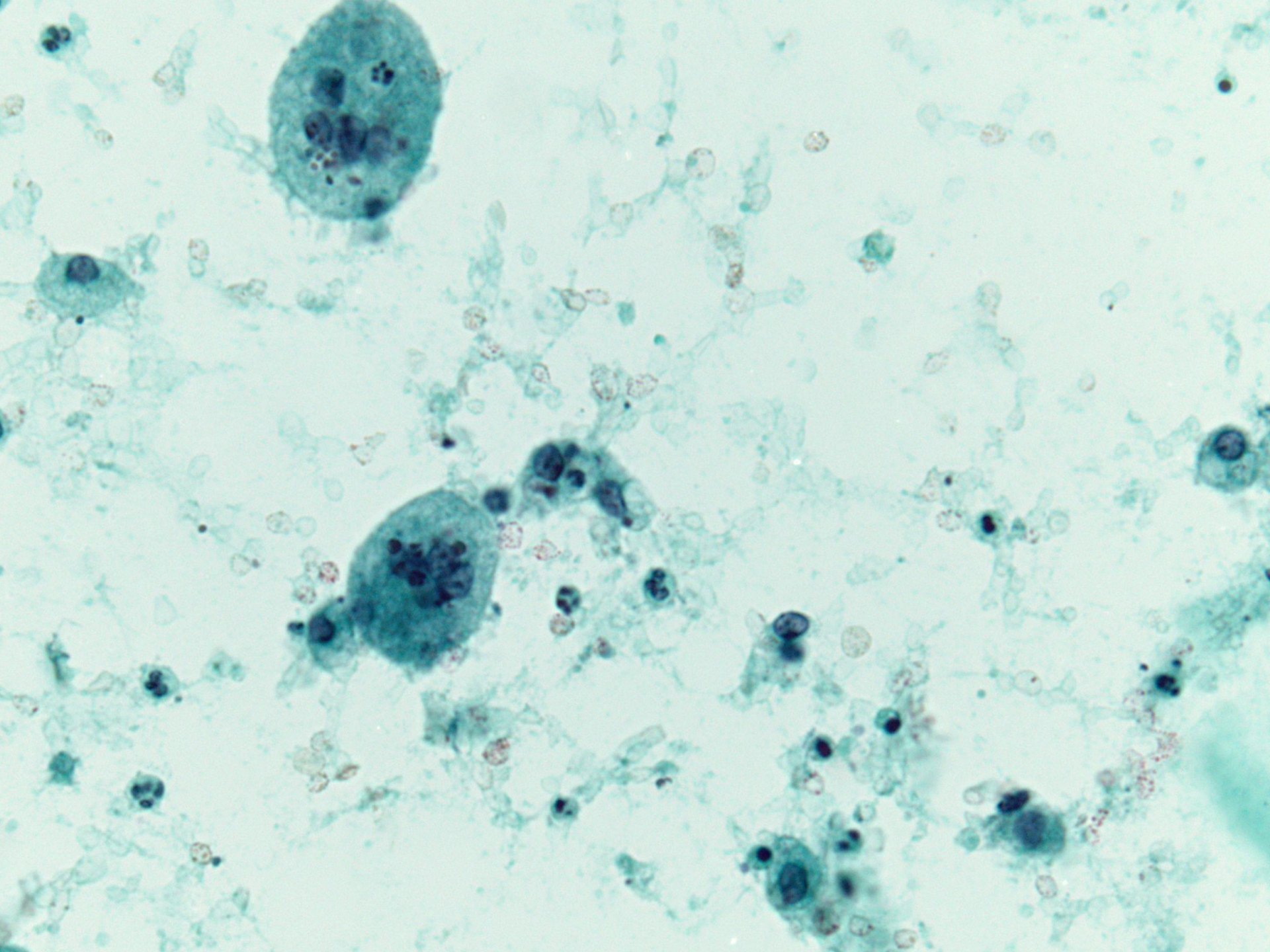
Apocrine metaplastic cells:  
Abundant cytoplasm, prominent nucleoli



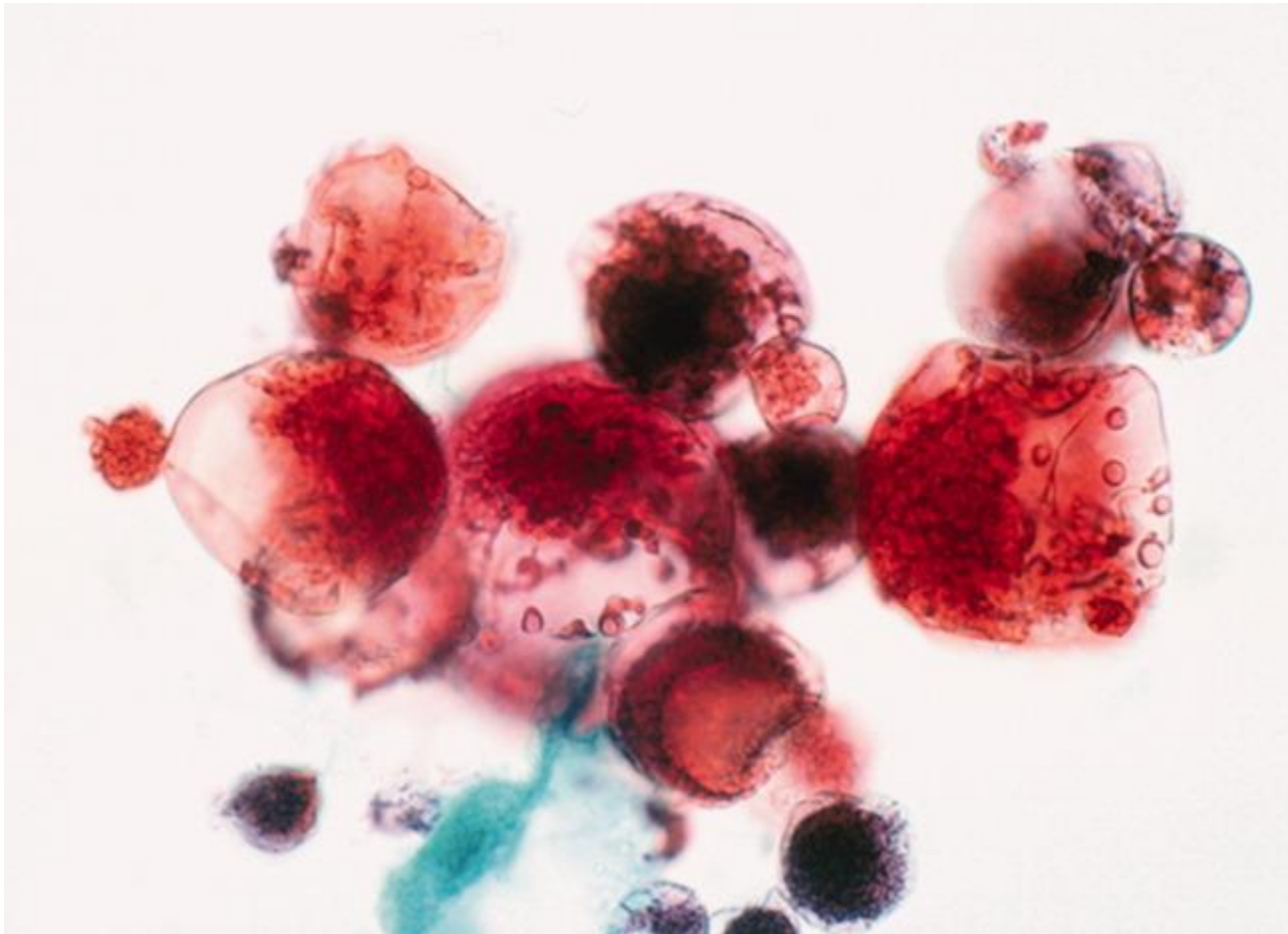


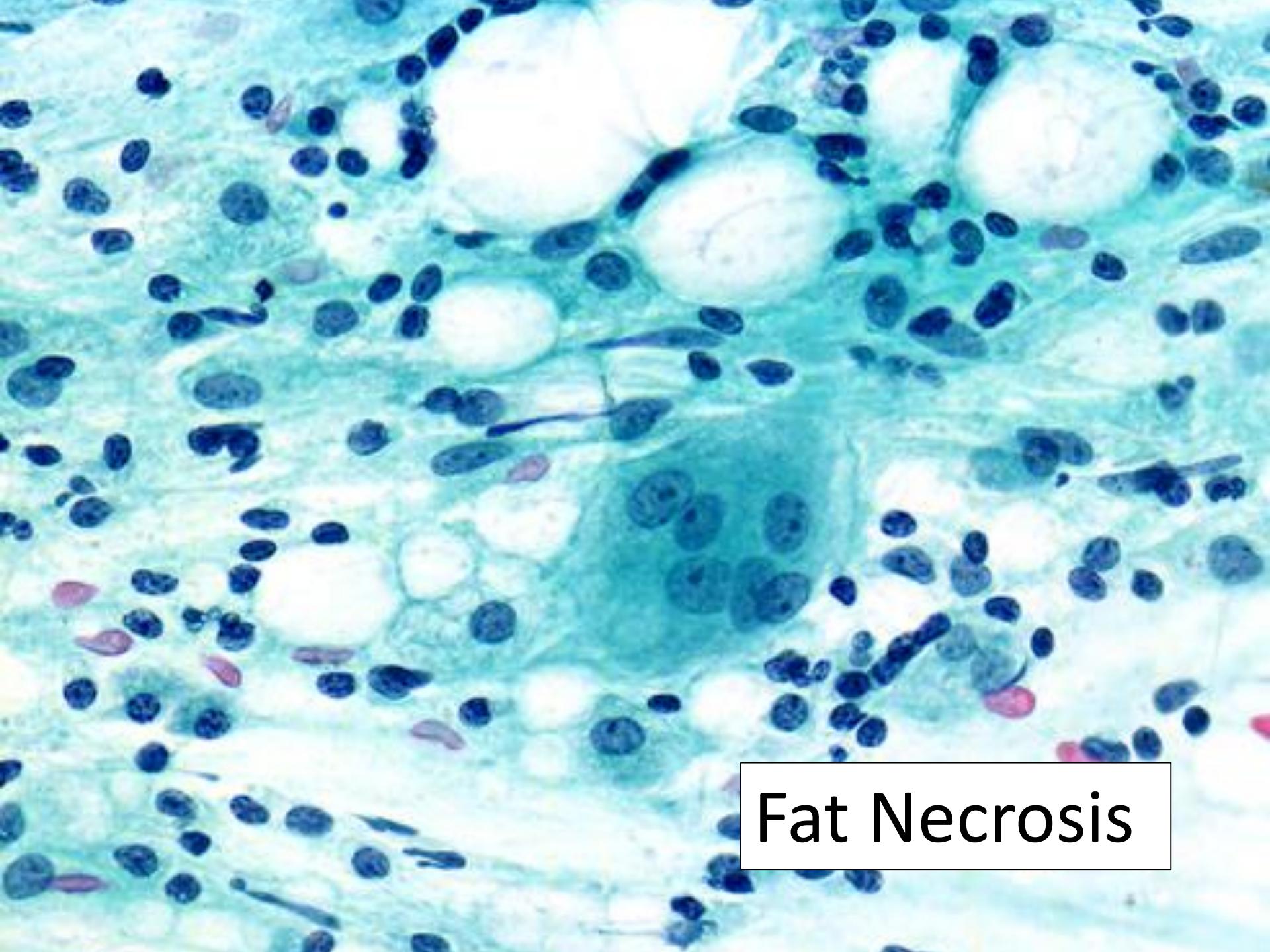
Abscess





# Myospherulosis





Fat Necrosis



## 2. Difficult to diagnose lesions

Inconclusive: C3 and C4

or

Erroneous

# Why the difficulty?

## 1. Technical:

- Low cellularity
- Air drying
- Obscuring factors

80%

Operator dependent

## 2. Inexperience of pathologist interpreting breast FNAs

## 3. Overlapping cytologic features of certain benign and malignant lesions (True grey zone)

20%

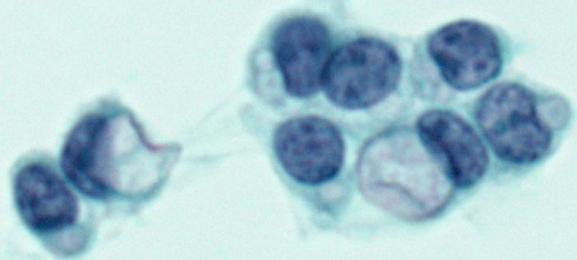
## Inconclusive or erroneous FNA of breast with adequate and representative material: Pathology/Cytology correlation. AUBMC 2003-2009

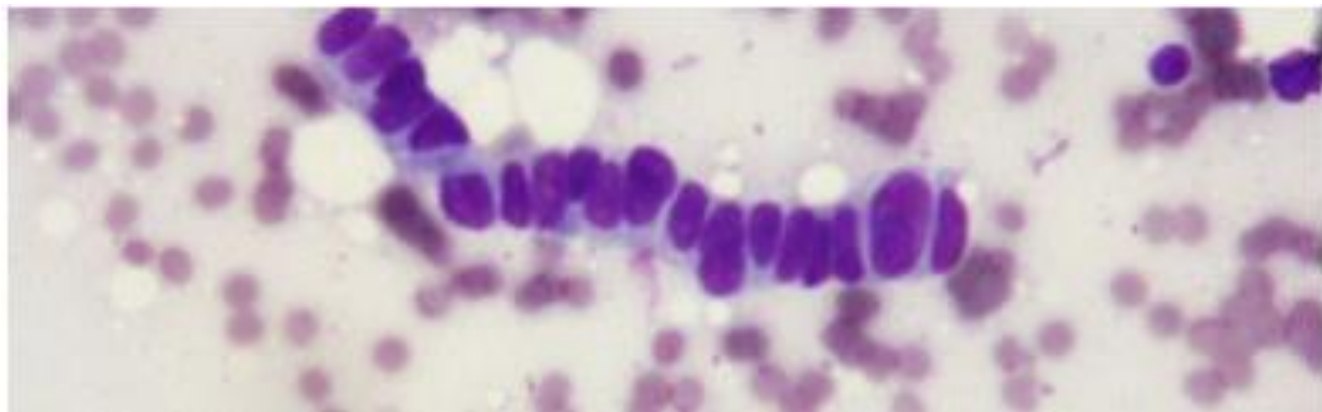
Case	Final diagnosis (Pathology)	FNA: Dx	FNA: Dx
1	<b>Adenomyoepithelioma</b>	C5	Adenocarcinoma
	<b>Fibro-epithelial tumors</b>		
2	Fibroadenoma	C3	
3	PT benign	C3	
4	PT malignant	C4	Suspicious for adenocarcinoma
	<b>Ductal carcinoma in situ</b>		
5	(cribriform)	C4	
6	(cribriform)	C2	FCC
	<b>Invasive carcinoma</b>		
7	cribriform	C4	
8	cribriform	C4	
9	Tubular	C4	
10	Tubular	C4	
11	Tubular	C2	fibroadenoma
12	Tubular	C4	
13	Lobular	C4	
14	Adenocarcinoma, nos grade 1/3	C4	
15	Adenocarcinoma. nos grade 1/3	C4	
16	Adenocarcinoma. nos grade 1/3	C4	
17	Adenocarcinoma, nos grade 2/3	C4	
18	Adenocarcinoma, nos grade 2/3	C4	
19	Adenocarcinoma, nos grade 2/3	C4	
20	Adenocarcinoma, nos grade 2/3	C4	
21	Adenocarcinoma, nos grade 2/3	C3	
	<b>Papillary lesions</b>		
22	Intraductal papilloma	C3	Papillary lesion
23	Encysted papillary carcinoma, non-invasive	C4	Papillary lesion
24	Encysted papillary carcinoma, invasive	C3	Papillary lesion

# Difficult to diagnose Mammary carcinomas

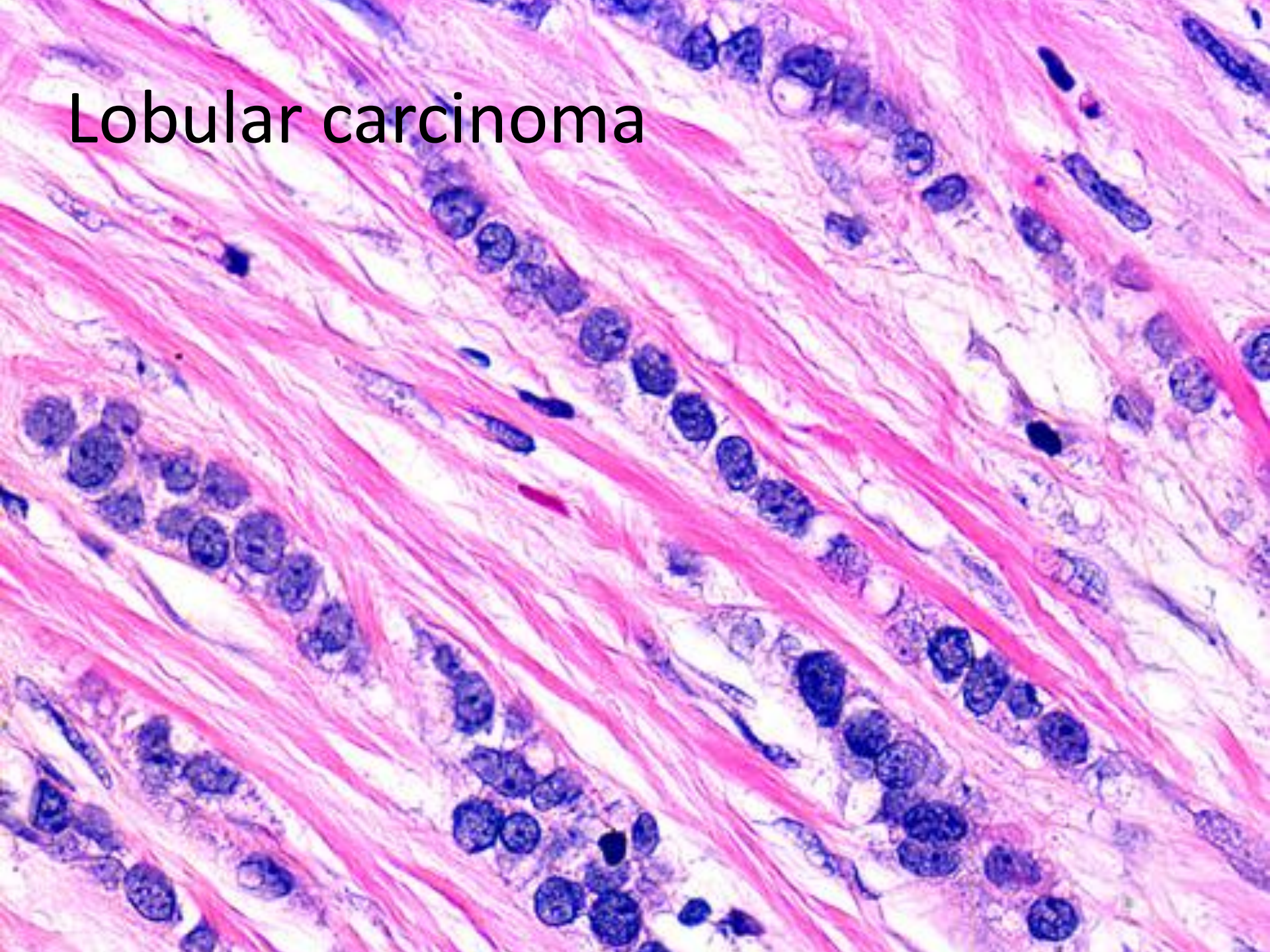
- Lobular Ca
- Mucinous
- Tubular Ca
- Papillary

Scant cellularity.  
Not V ugly



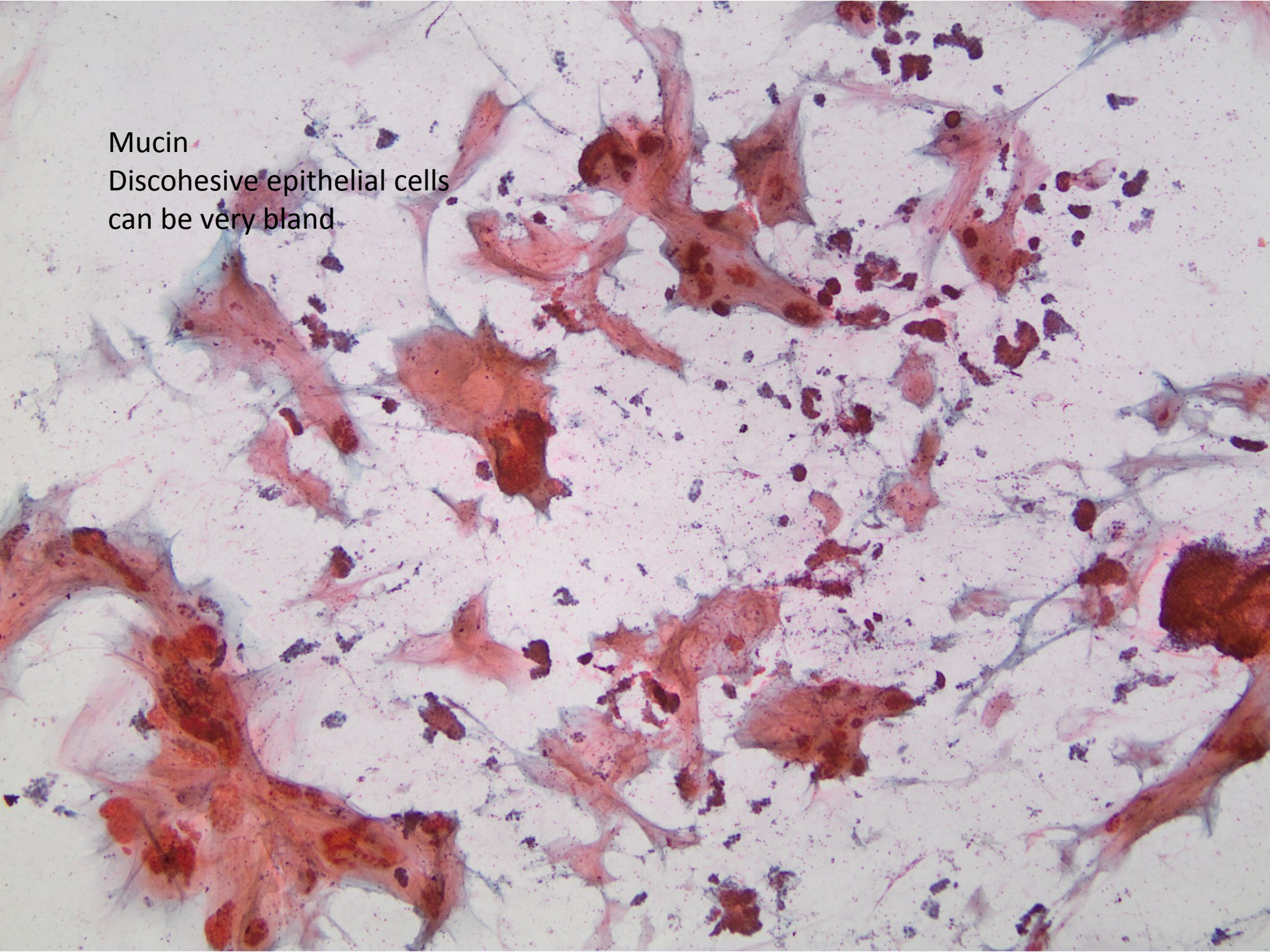


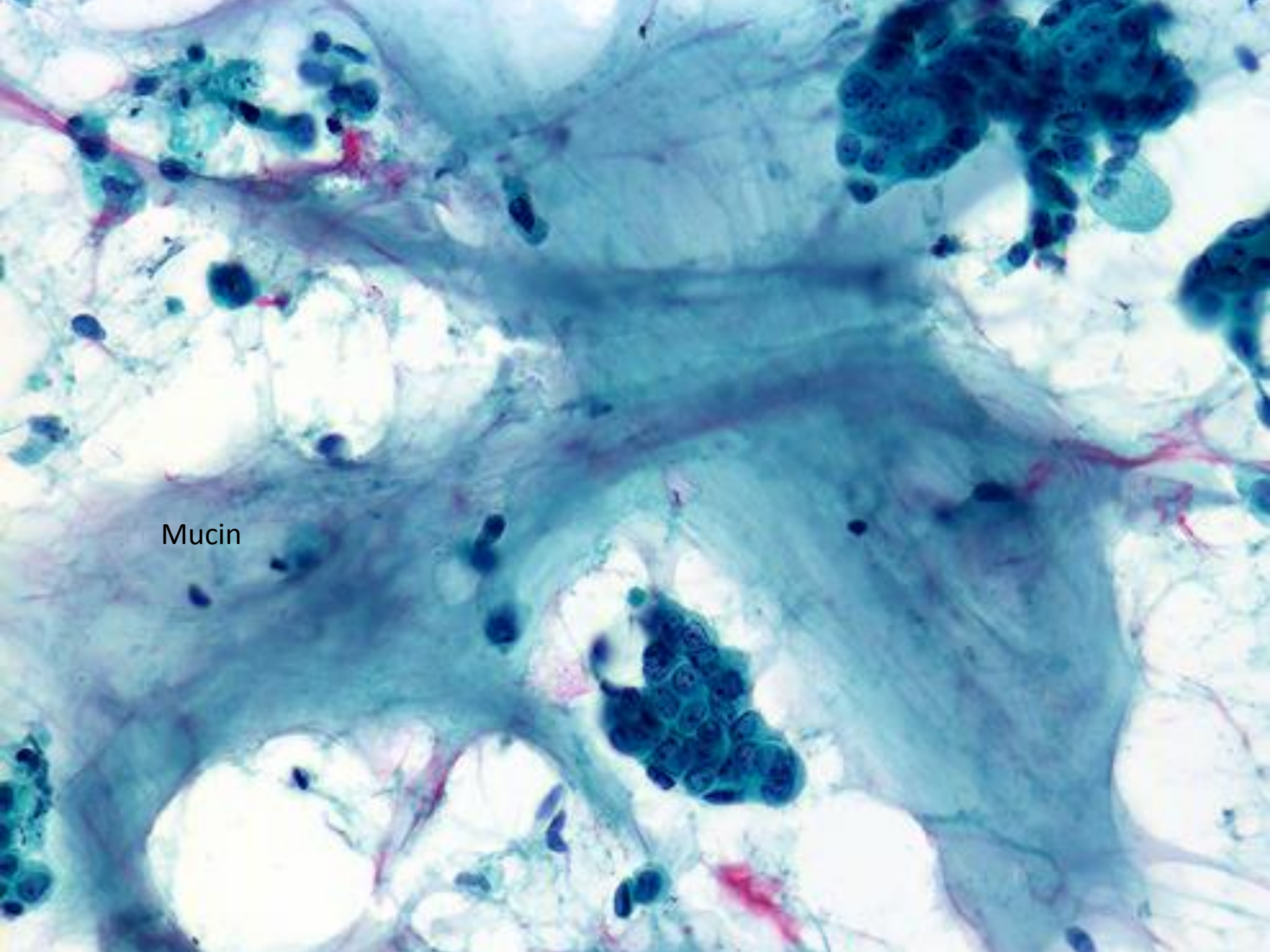
# Lobular carcinoma



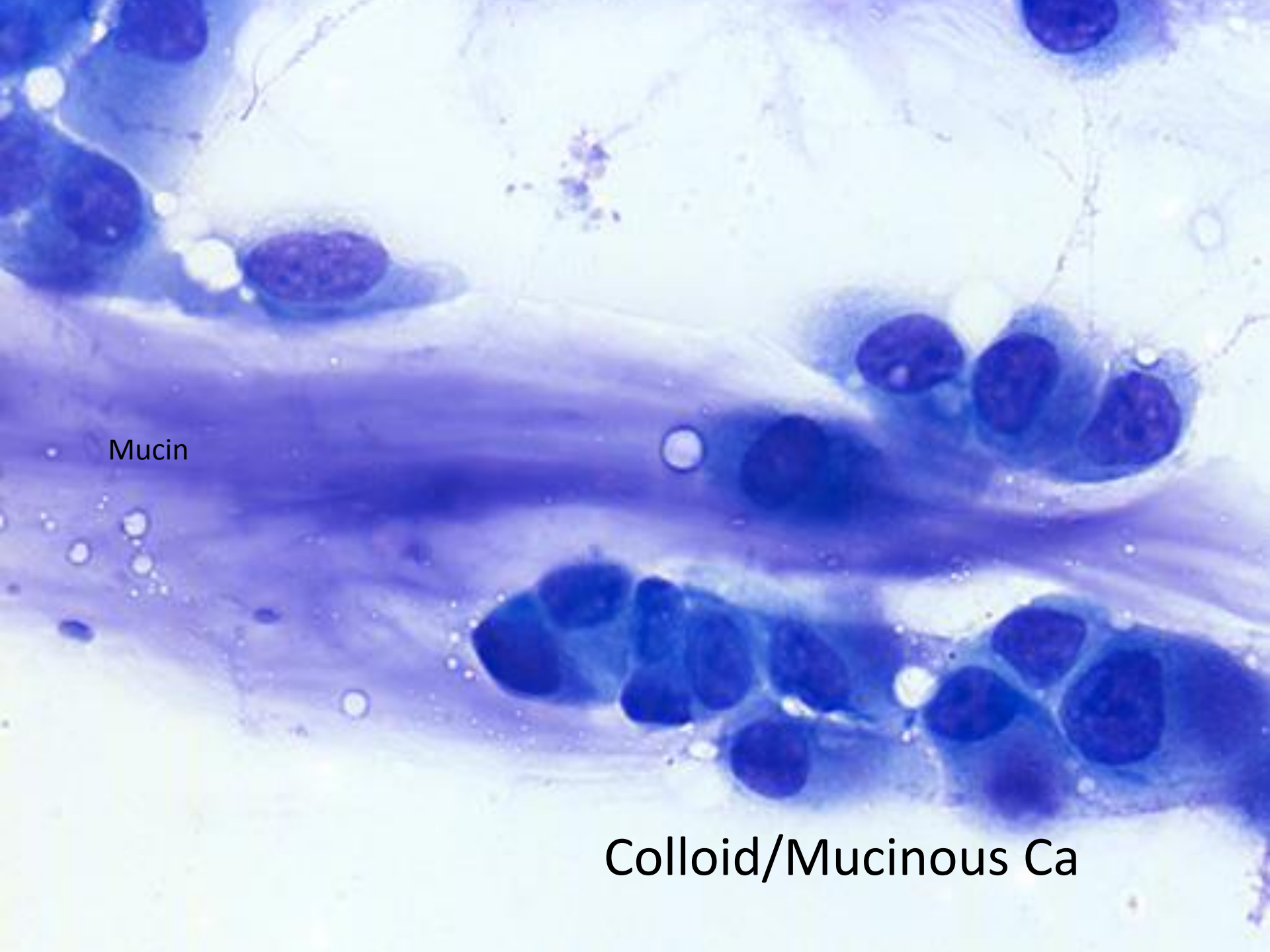Mucin

Discohesive epithelial cells  
can be very bland



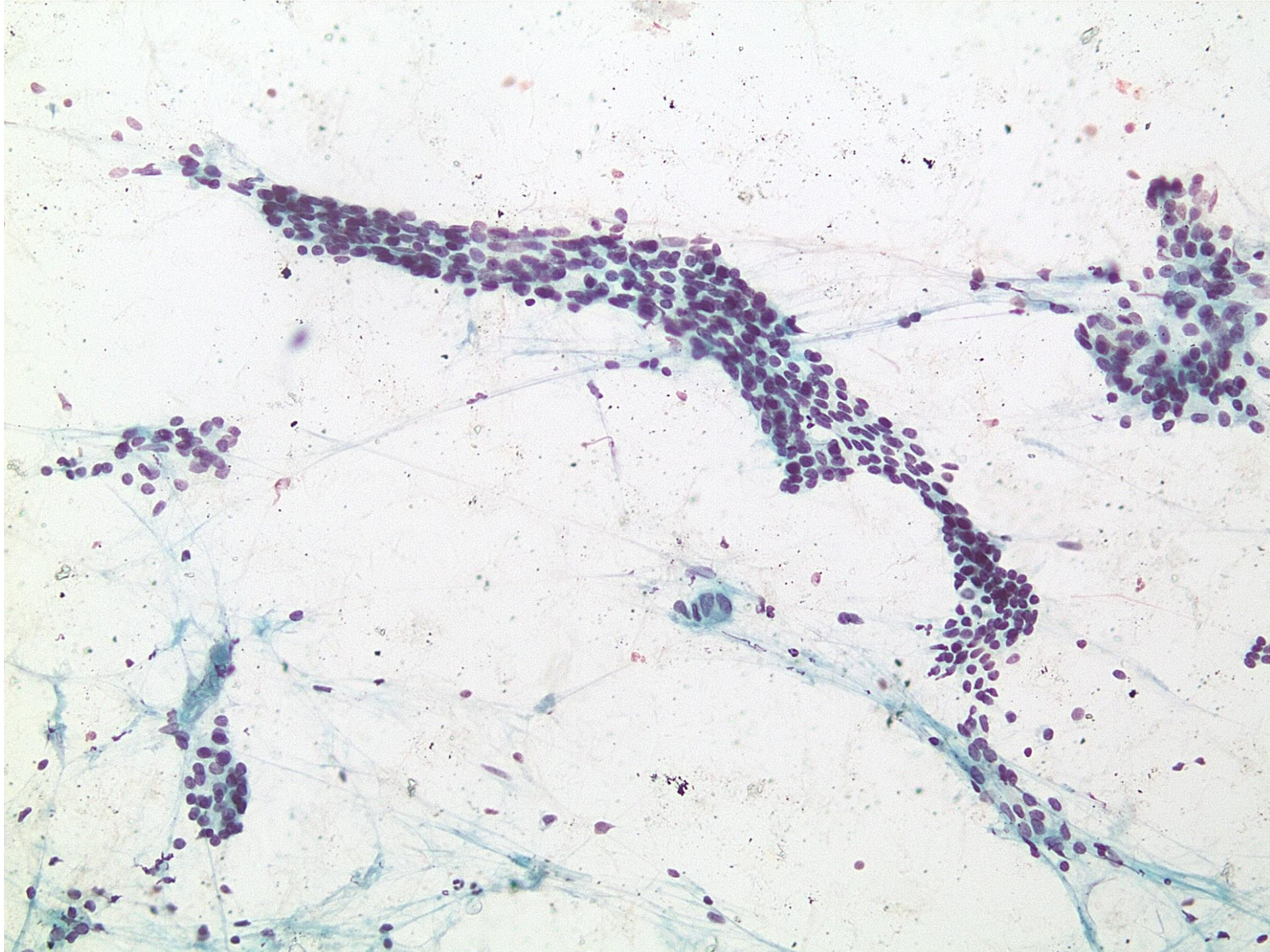


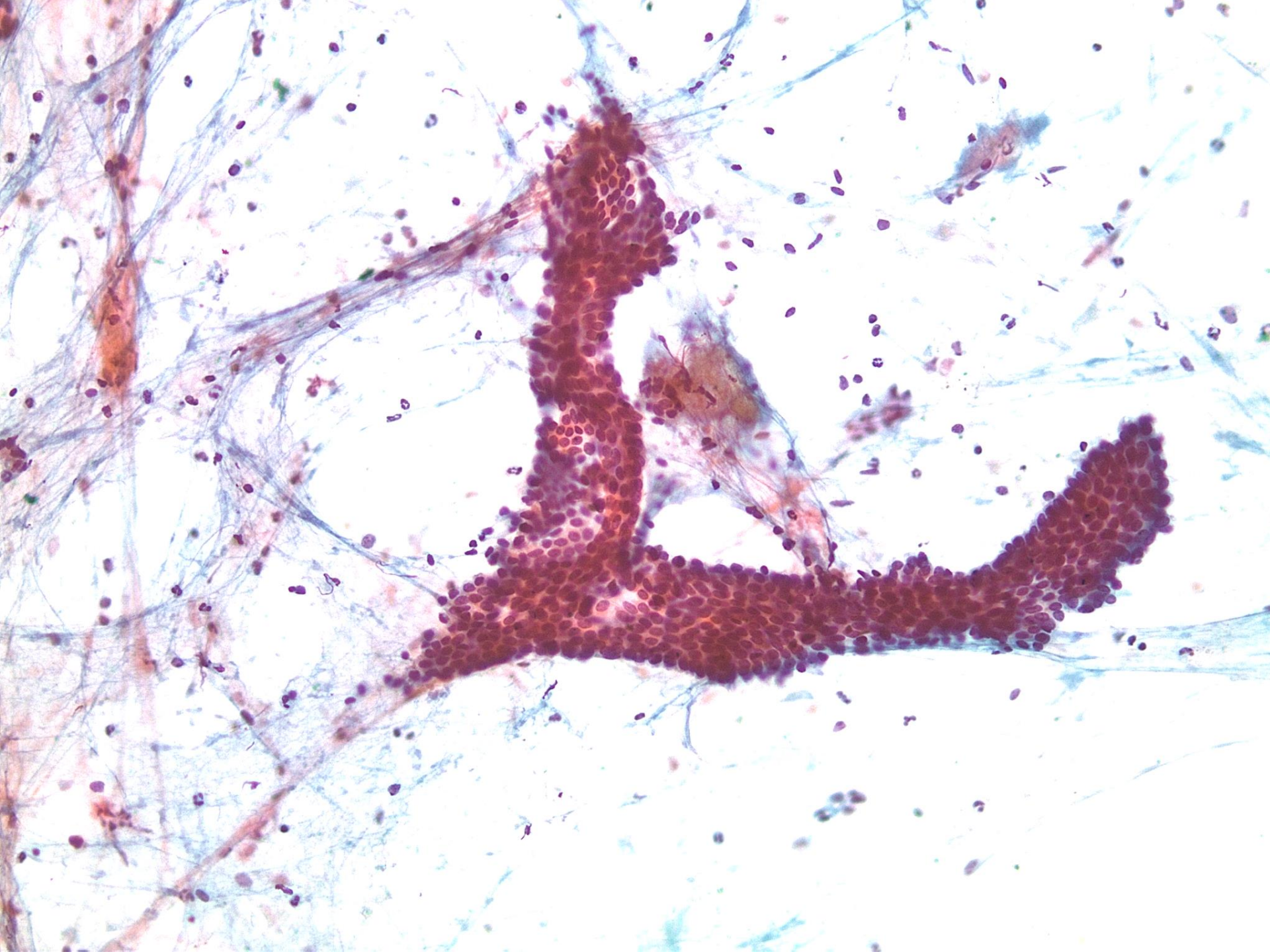
Mucin

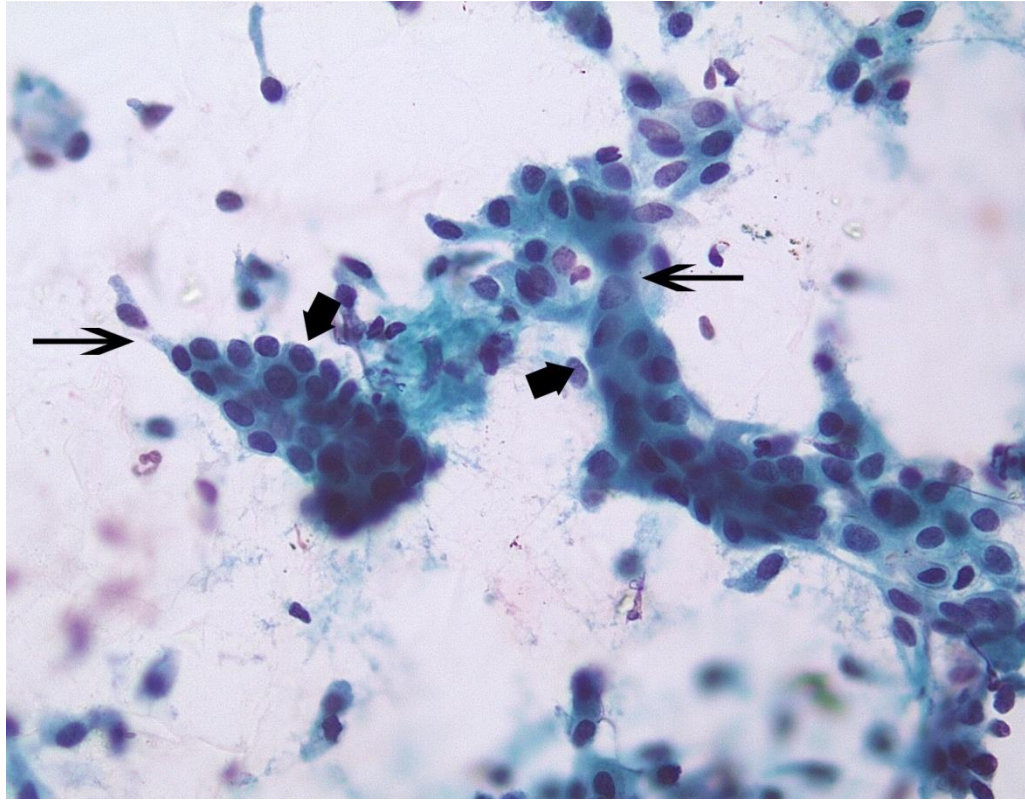


Mucin

Colloid/Mucinous Ca

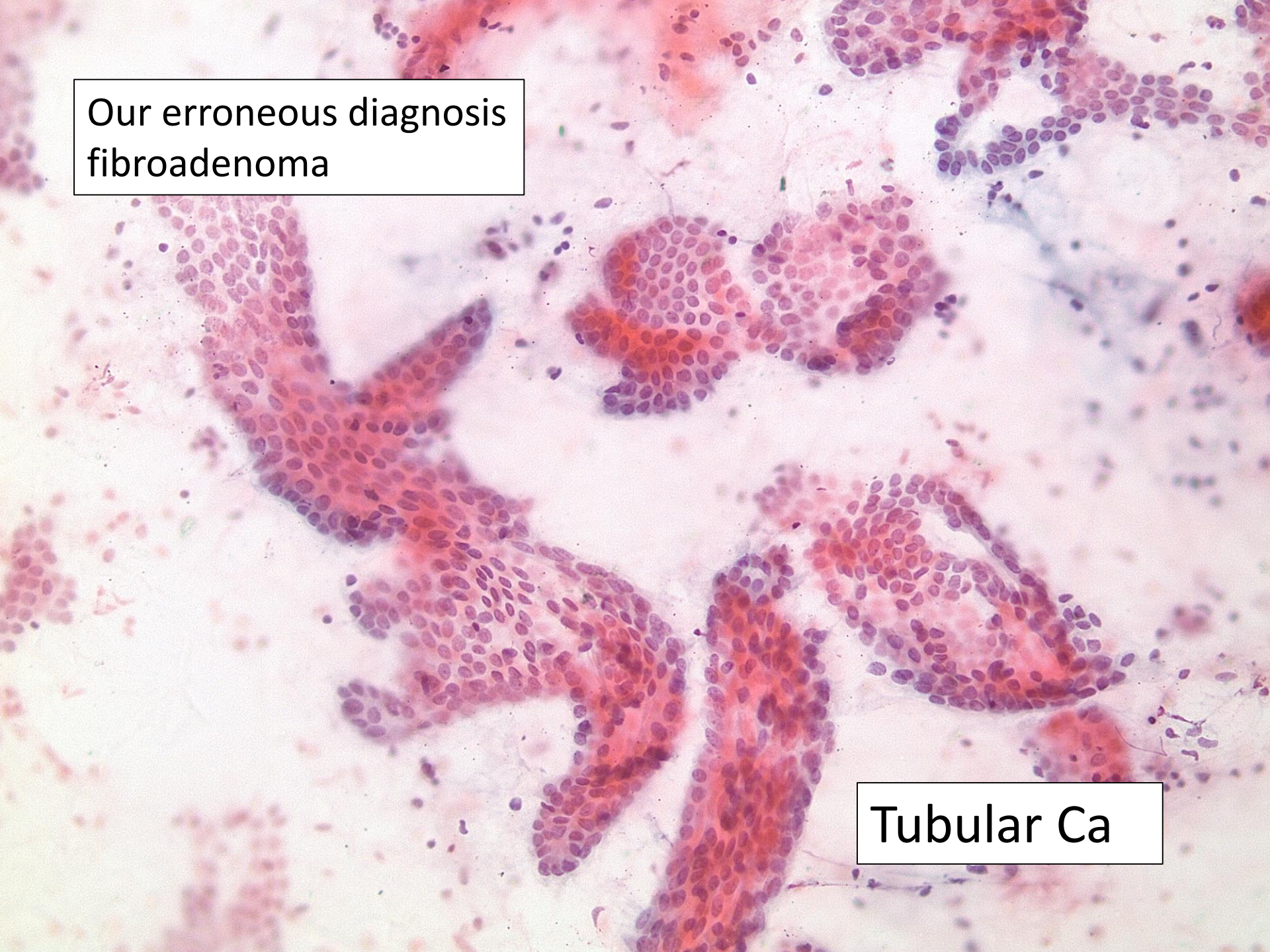




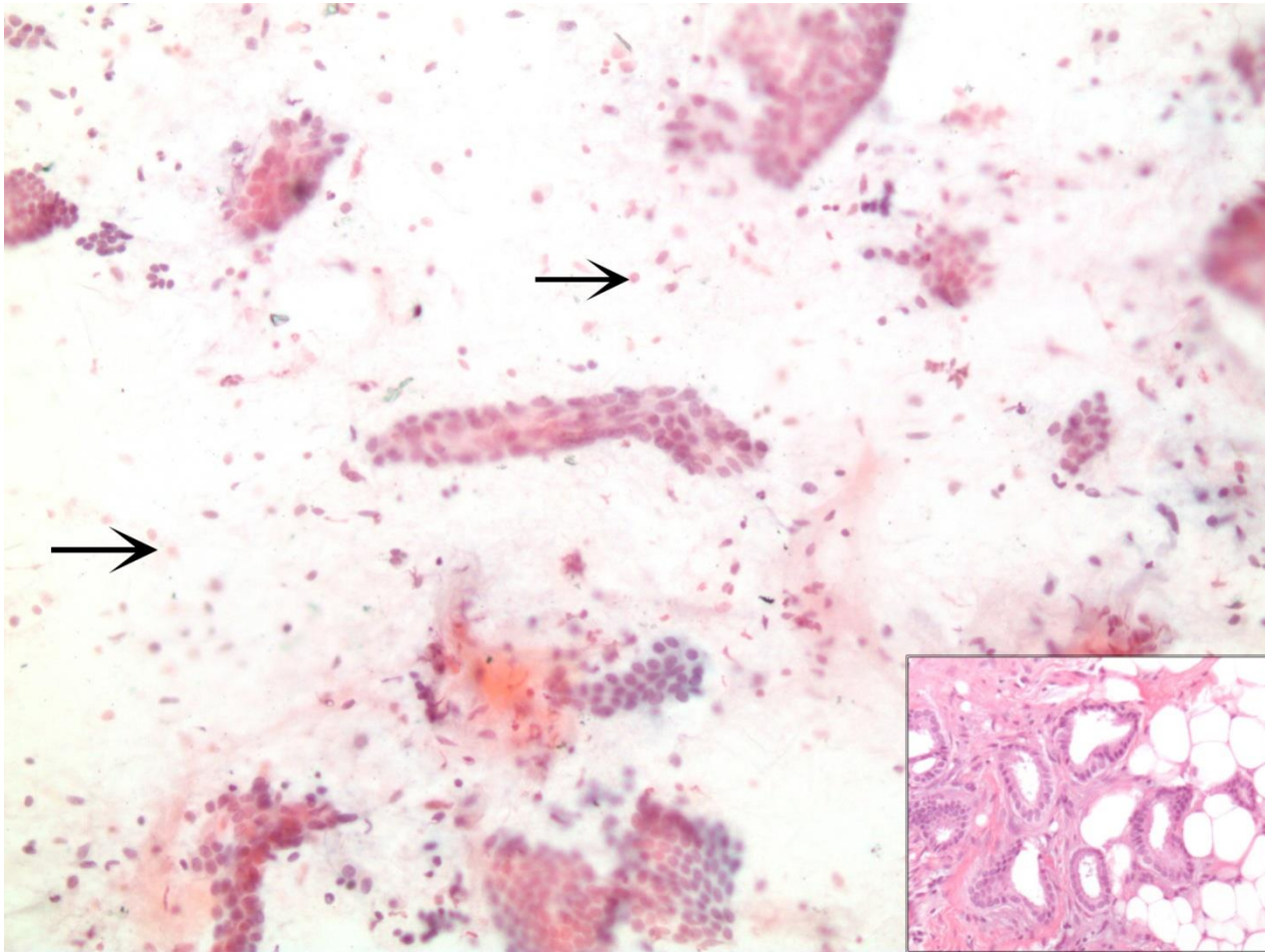


Our erroneous diagnosis  
fibroadenoma

Tubular Ca

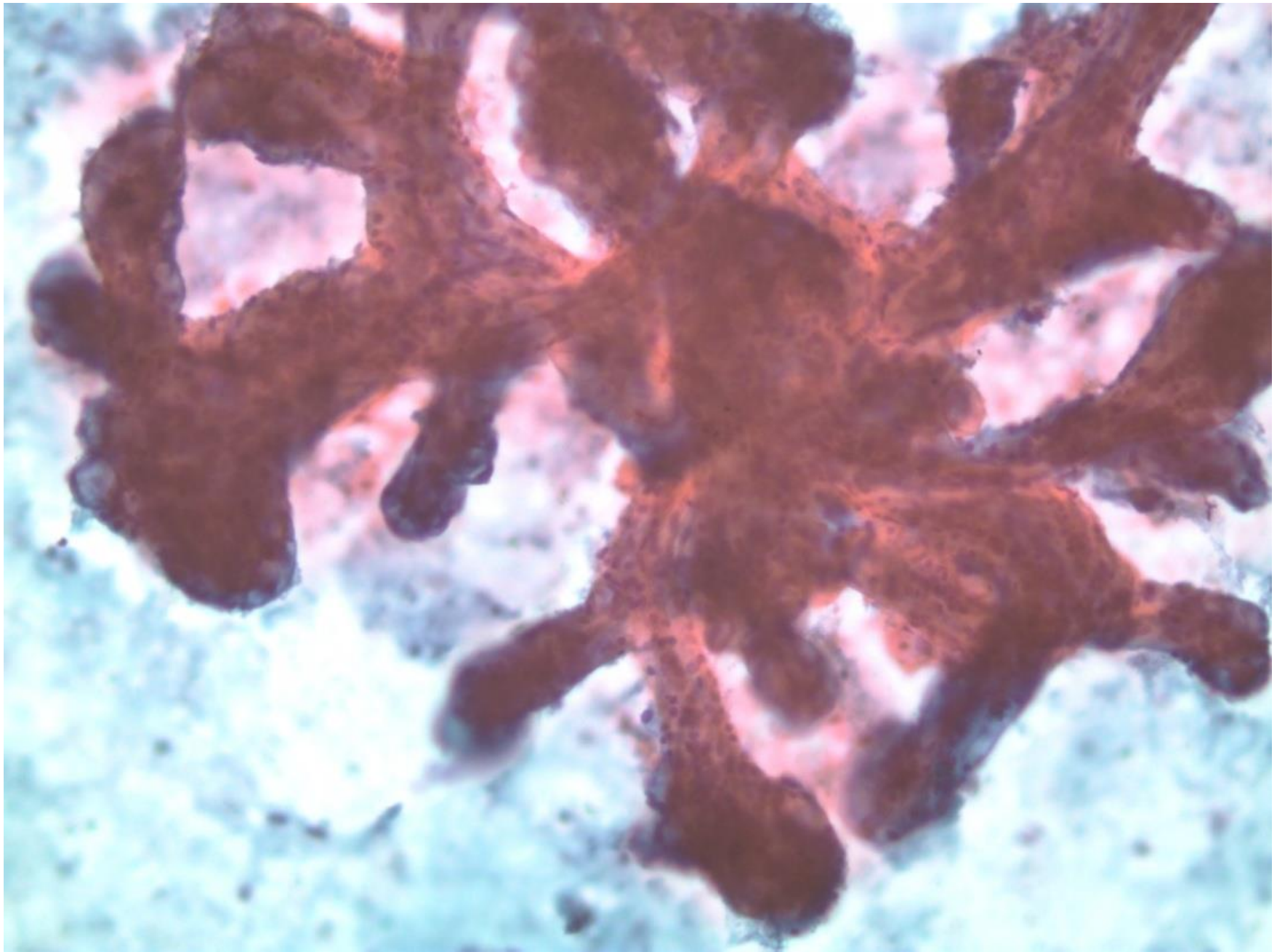


# Tubular carcinoma



# Tubular Ca

- Difficult to diagnose
- May resemble FA.
- Tubules: Numerous, rigid, abrupt change in diameter, ending in pointed tips, coma shaped projections.
- Gritty feel on aspiration very helpful.

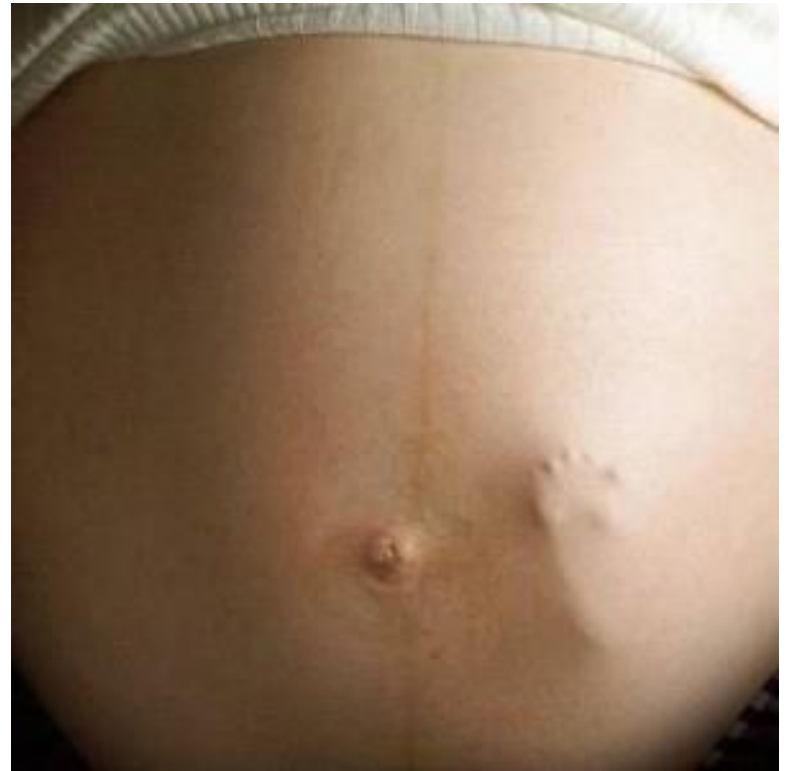

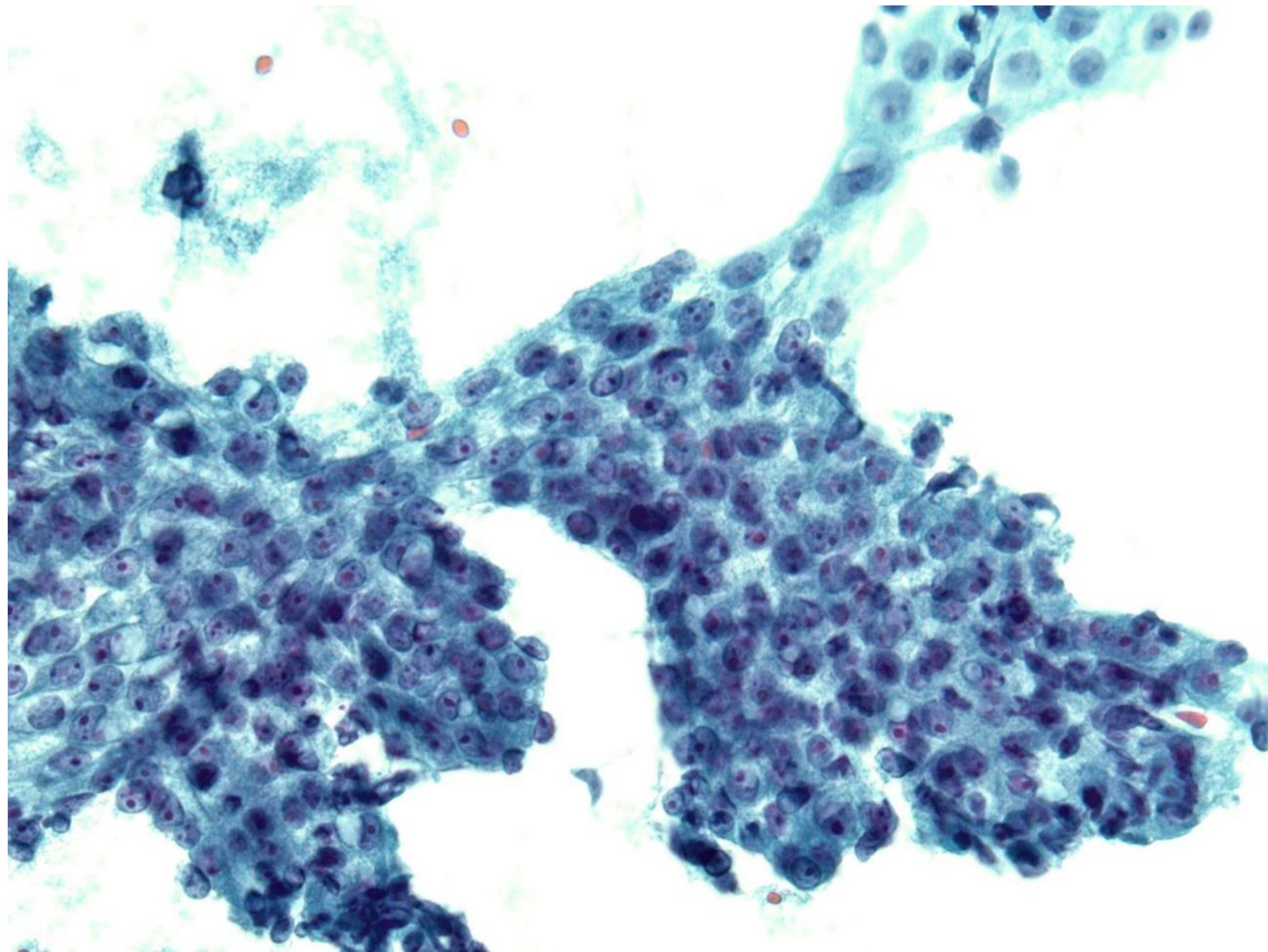
# Papillary lesions

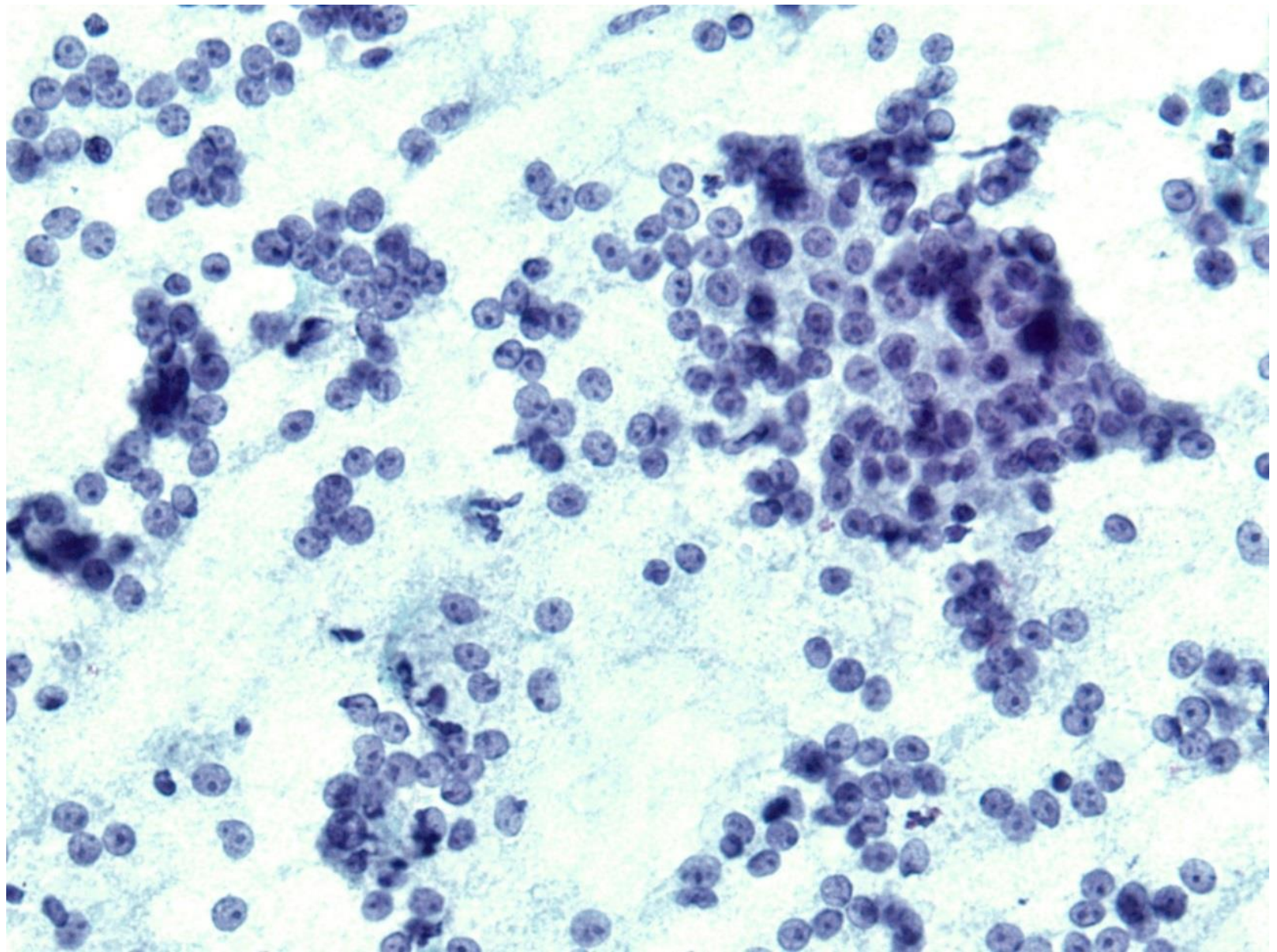
- Difficult distinguish benign from malignant
- Surgical excision is recommended.

# Common lesions in pregnancy/lactation

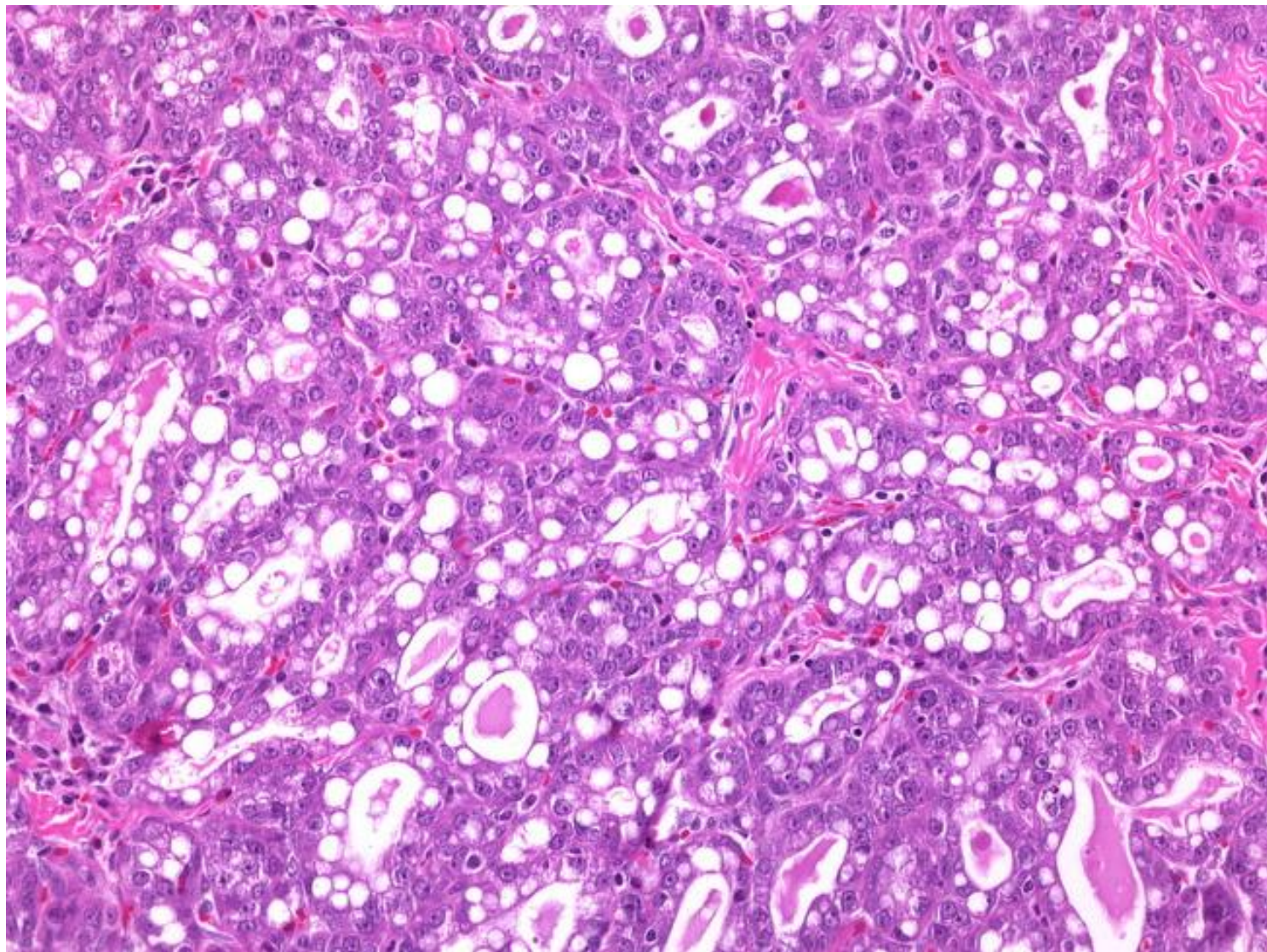
- Lactating adenoma
- Fibroadenoma
- Abscess
- Infiltrating Carcinoma (rare)







# Lactating Adenoma



# Lactating Adenoma

- Moderately cellular
- Abundant foamy background material
- Intact epithelial lobules small groups and single cells
- Uniform round nuclei, prominent nucleoli

# FNAs in pregnancy/lactation are difficult

- ↑ False Positive
  - Hormonal milieu → epithelial hyperplasia and cytologic atypia (mimic carcinoma)
- ↑ False Negative
  - Malignant tumors may be misinterpreted as lactation changes

# False positive

- Should be avoided at all cost
- Reported 1%

# False negative

- 7-10 %
- Very small and large lesions
- Desmoplastic tumors
- Malignancies with low grade nuclei

# Conclusion

# FNA of breast

- Replaced by core needle biopsies in most centers.
- Still has a role in some settings and some centers and third world countries.
- Cheap, rapid, reliable

# Easy to diagnose lesions

- Obviously malignant
- Obviously benign:
  - Fibroadenoma
  - FCC
  - Abscess
  - Fat necrosis

# Criteria for malignancy

1. ↑ ↑ cellularity
2. Loosely cohesive + individual tumor cells with intact cytoplasm
3. Variable degree of malignant cytologic features (ugliness)

